International Journal of Paleopathology 38 (2022) 41–44

Contents lists available at ScienceDirect

International Journal of Paleopathology

journal homepage: www.elsevier.com/locate/ijpp

Inner ear modifications in Dar-es-Soltane II H5 (Morocco): A case of labyrinthitis ossificans

Dany Coutinho-Nogueira [a,b,c,*], Hélène Coqueugniot [a,b], Olivier Dutour [a,b], Abdelouahed Ben-Ncer [d], Jean-Jacques Hublin [e,f]

[a] Univ. Bordeaux, CNRS, MCC, PACEA, UMR, 5199 Pessac, France
[b] EPHE, PSL University, Paris, France
[c] University of Coimbra, CIAS - Research Centre for Anthropology and Health, Department of Life Science, Coimbra, Portugal
[d] Institut National des Sciences de l'Archéologie et du Patrimoine, Rabat, Morocco
[e] Collège de France, Paris, France
[f] Dept. of Human Evolution, Max Planck Institute for Evolutionary Anthropology MPI-EVA), Leipzig, Germany

ARTICLE INFO

Keywords:
Bony labyrinth
Temporal bone
Micro-CT scan
Ossification
Labyrinthitis ossificans

ABSTRACT

Objective: This paper presents the inner ear modifications in Dar-es-Soltane II H5, an Aterian fossil possibly dated to 100 ka.
Material: The remains consist of a large portion of the cranium including the face, the left frontal and temporal bones, part of the left parietal bone and greater wing of the sphenoid.
Methods: The bony labyrinth anatomy was investigated on existing micro-CT data acquired by the MPI-EVA.
Results: The observation of micro-CT sections revealed a partial filling of the semi-circular canals that raises question about its origin. A careful examination of the micro-CT sections shows that the elements present in the semicircular canals were denser than the sediments observed in other regions and cavities of the temporal bone.
Conclusions: The current evidence suggests a pathological origin of this condition with partial ossification of the membranous labyrinth. The differential diagnosis indicates a case of labyrinthitis ossificans in its early stages.
Significance: This pathological condition can be responsible for permanent hearing loss and is associated with dizziness and vertigo. Along with the Singa skull, Dar-es-Soltane II H5 represents one of the oldest known cases of labyrinthitis ossificans.
Limitations: The early stage of disease and the absence of the right temporal bone limit conclusions about the degree of disability of the individual and their dependence on the rest of the group.
Suggestions for further research: To carry out a paleopathological study of all the fossils from Dar-es-Soltane II.

1. Introduction

The temporal bone and inner ear are of great interest to paleoanthropologists since they are useful indicators of hominin phylogeny (Spoor, 1993). Indeed, numerous publications used bony labyrinth morphology for distinguishing Neanderthals from modern humans (e.g. Hublin et al., 1996; Spoor et al., 2003; Hill et al., 2014; Gómez-Olivencia et al., 2015).

The study of the otic capsule within the petrous bone requires the use of (micro) computed tomography (CT) scans, which in some cases reveal changes in the bone that are not observable macroscopically. These changes can have a taphonomic origin (postmortem) or a pathological origin that can have consequences on the individual's life that may include loss of hearing, dizziness, and vertigo.

The purpose of this study is to analyze the changes detected in the bony labyrinth of Dar-es-Soltane II H5 and understand their etiology using micro-CT imaging.

2. Material and methods

Dar-es-Soltane II cave was excavated during the 1970′s under the supervision of A. Debénath. It is located near El Menzeh (Rabat,

* Correspondence to: CIAS - Research Centre for Anthropology and Health, Departamento de Ciências da Vida, Universidade de Coimbra, Calçada Martim de Freitas, 3000-456 Coimbra, Portugal.
E-mail addresses: dany.nogueira@uc.pt (D. Coutinho-Nogueira), helene.coqueugniot@u-bordeaux.fr (H. Coqueugniot), olivier.dutour@ephe.psl.eu (O. Dutour), abdelouahed.benncer@insap.ac.ma (A. Ben-Ncer), jean-jacques.hublin@college-de-france.fr (J.-J. Hublin).

https://doi.org/10.1016/j.ijpp.2022.06.004
Received 25 November 2021; Received in revised form 8 June 2022; Accepted 9 June 2022
Available online 6 July 2022
1879-9817/© 2022 Elsevier Inc. All rights reserved.

Morocco). The site has delivered a long stratigraphy from the cultural period of the Aterian to the Neolithic. As far as the Aterian is concerned, the human remains of 3 individuals have been identified: an adult cranium and hemi-mandible (named H5), a fragment of mandible and maxilla belonging to an individual whose dental maturation was not fully completed and a calvaria belonging to a child. All these human remains originate from layer 7 (Debenath, 1976; Ferembach, 1976). Amino racemization ratios in molluscs provide dates between 85 and 75 ka for layer 7 (Raynal and Occhietti, 2012) while optically stimulated luminescence dating indicates an age of 121.7 ± 8.2 ka (Schwenninger et al., 2010).

The remains of Dar-es-Soltane II H5 consist of an almost complete frontal bone and a large portion of the left side of the cranium including the face, temporal bone, part of the parietal bone and greater wing of the sphenoid. Early descriptions suggested that Dar-es-Soltane II H5 is a male over 50 years of age. These estimations, only based on partial cranial remains, should be considered with caution (Ferembach, 1976). Recent studies of the cranium and inner ear morphology suggest close morphological affinity between Dar-es-Soltane II H5 and the Qafzeh individuals from the Levant (Harvati and Hublin, 2012; Coutinho-Nogueira et al., 2021).

Micro-CT data of Dar-es-Soltane II H5 was acquired by the MPI-EVA (isometric voxels: 0.099 mm). CT scan sections were analyzed using TIVMI® software v2.3 (Dutailly et al., 2009). In order to compare the modifications observed in Dar-es-Soltane II H5, we used CT scans from Qafzeh 9 and 25 early modern humans (Supplemental Information 1).

Bone changes were analyzed using traditional methods for differential diagnosis in paleopathology (Ortner, 2003; Aufderheide and Rodríguez-Martín, 1998; Dutour, 2011).

3. Results

Analysis of the micro-CT scan slices revealed that the lateral and posterior semicircular canals are partly filled with high-density material (Fig. 1). The otic capsule in this region showed a high density compared to what is visible in the anterior canal. The material is irregular, but some portions of the two canals are completely obliterated (Fig. 2). The bone surrounding the cochlea also presents high density (Fig. 3). Some sediment is present in the cavities of the temporal bone. Sediment is easily identified on the micro-CT scan by its heterogeneous density (Fig. 4).

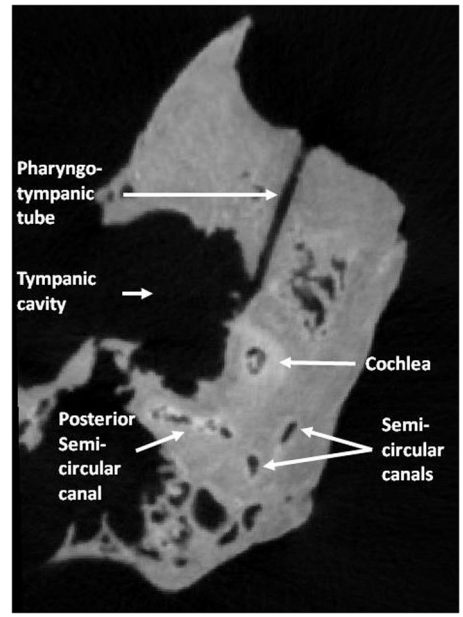

Fig. 2. Partly filled posterior semi-circular canal with high-density material, other structures such as the pharyngo-tympanic tube and the tympanic cavity are free of material (transverse plane).

4. Discussion

4.1. Density of the otic capsule and changes in the semi-circular canals

The higher bone density surrounding the cochlea is not observed in fossils from Qafzeh site (Supplemental Information 2). However, we cannot exclude that fossilization conditions in this site and the quality of the scan limit the interpretation of this observation. As the posterior and lateral semicircular canals present higher density than the anterior one,

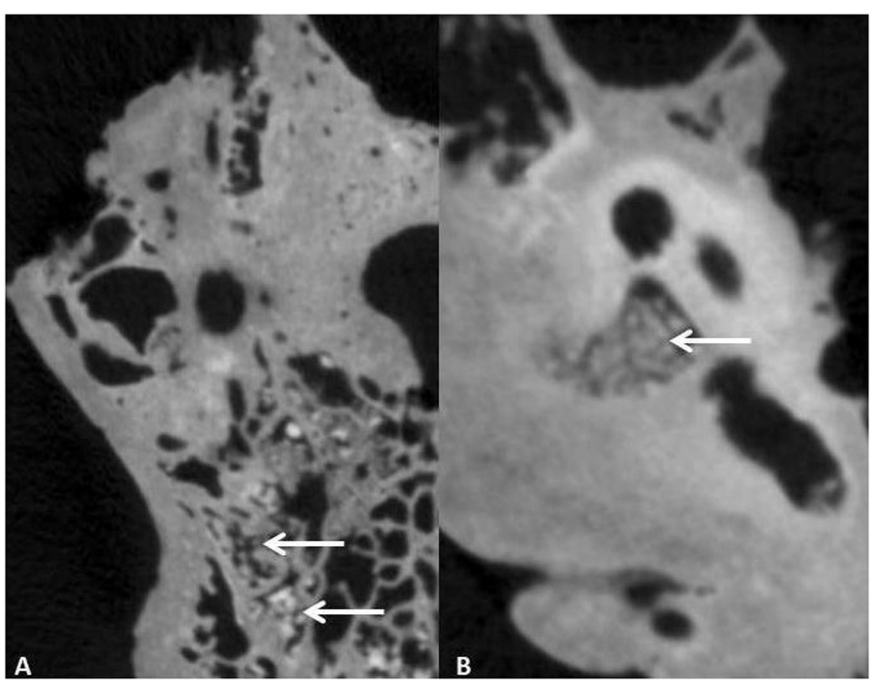

Fig. 1. Sediment with heterogeneous density in (A) the mastoids cells and (B) the internal acoustic canal (transverse plane).

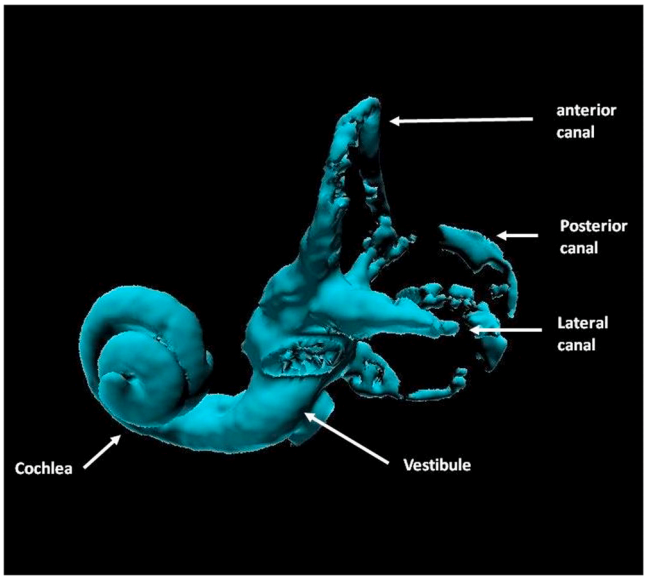

Fig. 3. 3D reconstruction of the bony labyrinth revealing the obliterated parts of the posterior and lateral canals.

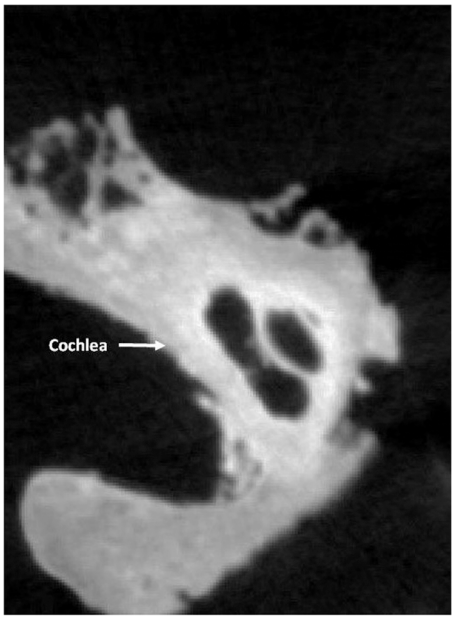

Fig. 4. Osteocondensation around the cochlea (transverse plan).

we assumed that these changes are due to a pathological condition. Indeed, changes due to otoclerosis (Sanghan et al., 2018) or labyrinthitis ossificans (Paparella and Sugiura, 1967) can provoke a thickening of the otic capsule.

Due to its high and homogeneous density, the material present in the semicircular canals cannot be of sedimentary origin. Indeed, sediment found in other regions and cavities of the temporal bone has a lower and heterogeneous density.

4.2. Differential diagnosis

Few pathologies affecting the bony labyrinth can produce new bone, and otosclerosis and labyrinthitis ossificans are the most common causes. The presence of the canals excludes complete labyrinthine aplasia (Ozgen et al., 2009).

Otosclerosis is characterized by an abnormal hardening of tissues in the inner and middle ear leading to conductive, sensorineural or mixed hearing loss. Sclerosis mostly occurs during the 2nd to 4th decades of life (Purohit et al., 2014). The sex ratio is 2:1, with females being more affected than males. The etiology of this pathology involved multiple factors both genetic and epigenetic. Ossification of the membranous labyrinth can occur in rare cases of cochlear otosclerosis, and it only affects the cochlea, leaving the semi-circular canals intact (Swartz and Mukherji, 2009). Furthermore, the sclerosis of the soft tissues (around the stapes and the basal turn of the cochlea) is characterized by the production of spongy and vascular bone, associated with demineralization of the otic capsule in the cochlear region (Purohit et al., 2014). However, some phases during the remodeling provoke a thickening of the otic capsule (Sanghan et al., 2018). Retro-fenestral (cochlear) otosclerosis is considered to be the continuation of a fenestral form where the stapes is fixed by the ossification of ligaments (Purohit et al., 2014).

Otosclerosis can be ruled out here because of: 1) the location of the new bone formation in the cochlea, 2) the spongy and vascular nature of the newly formed bone, 3) the demineralization of the otic capsule and 4) the absence of involvement of the semicircular canals.

Labyrinthitis ossificans (LO) is characterized by the ossification of the membranous labyrinth. The disorder is responsible for permanent unilateral or bilateral sensorineural hearing loss and positional vertigo. Ossification generally occurs after a fibrous phase which affects hearing and balance (Paparella and Sugiura, 1967).

This pathological condition usually results from a local infection: chronic otitis or bacterial meningitis (Swartz et al., 1985); other possible etiologies include trauma, autoimmune disease and tumors (Huang et al., 2012; Buch et al., 2019); vascular disorders are also considered a possible cause (Taxak and Ram, 2020). Hearing loss and positional vertigo can occur shortly after the infectious or traumatic event (4 weeks; Larson et al., 2016), ossification can be detected 3–4 months after initial insult (Taxak and Ram, 2020), but many years are needed for complete ossification (Paparella and Sugiura, 1967). The sex ratio is 1.5:1; with females being more affected, individuals between 30 and 50 years old are more commonly affected (Taxak and Ram, 2020).

Tympanogenic labyrinthitis subsequent to chronic otitis is considered to be the principal etiology of infectious labyrinthitis and can initiate through the oval window or the lateral semicircular canal (Swartz et al., 1985). In this case, only one side is generally affected (Huang et al., 2012). Bacterial meningitis is also a common cause and spreads through three possible routes: subarachnoid space, cochlear aqueduct, and internal auditory canal; ossification is generally bilateral (Swartz et al., 1985; Kaplan et al., 1984).

The ossifications of the semicircular canals of Dar-es-Soltane H5 II may be the result of LO, as the inner ear changes observed are consistent with this condition. It is difficult to assess the precise cause of LO, although tympanic infection seems the most likely cause, with spread through the lateral canal, which is more commonly involved in cases of LO secondary to otitis (Buch et al., 2019). No evidence of antemortem trauma, tumor or vascular disorder affecting the bony labyrinth or on the temporal bone are visible. However, none of them can be excluded, as they could have affected non-fossilized tissues.

4.3. Consequences on the daily life of Dar-es-Soltane II H5

As the cochlea seems to be relatively unaffected by the new bone formation, we cannot exclude that the calcification process (fibrous phase) was in progress at the time of death of the individual but not developed enough to fossilize. It is difficult to determine the level of hearing loss and therefore the level of disability that this pathology could have caused, especially since the absence of the right temporal bone makes it impossible to know if the other cochlea was affected. However, the ossification affecting two of the three semicircular canals may have impacted equilibrium, causing dizziness and vertigo. For nomadic populations, this handicap can limit the efficiency of hunting

and food acquisition. The early stage of ossification indicates that death occurred only a few months after the beginning of this pathological condition.

5. Conclusion

Paleoimaging was essential for detecting and identifying the changes in the bony labyrinth of Dar-es-Soltane II H5. The partial ossification of the semicircular canals is the consequence of labyrinthitis ossificans, probably resulting from a chronic ear infection. The disease may have caused equilibrium disorders such as dizziness and positional vertigo, and possible hearing loss. The individual's limited survival time after the onset of this condition calls into question the cause of death and care this individual may have received.

Declarations of interest

none.

Acknowledgements

We would like to thank Anne-marie Tillier (CNRS, UMR PACEA, Pessac) for her comments and suggestions, Heiko Temming (Max Planck Institute for Evolutionary Anthropology, Leipzig) for his technical help and Israel Hershkovitz (Dan David Center, University of Tel Aviv) for the access to the Qafzeh CT scans. We thank the two anonymous reviewers, the associate editor and the editor for their comments and recommendations to improve the quality of the manuscript. We would like to thank John C. Willman (Universidade de Coimbra) for the English editing. The first author has been supported by a research and travel grant from the Irene Levi Sala Care Archaeological Foundation, Switzerland. Additional support was provided by the LaScArBx (ANR-10-LABX-52), France.

Appendix A. Supporting information

Supplementary data associated with this article can be found in the online version at doi:10.1016/j.ijpp.2022.06.004.

References

Aufderheide, A.C., Rodríguez-Martín, C., 1998. The Cambridge Encyclopedia of Human Paleopathology, 498. Cambridge University Press, Cambridge.

Buch, K., Baylosis, B., Fujita, A., Qureshi, M.M., Takumi, K., Weber, P.C., Sakai, O., 2019. Etiology-specific mineralization patterns in patients with labyrinthitis ossificans. Am. J. Neuroradiol. https://doi.org/10.3174/ajnr.A5985. A5985v1.

Coutinho-Nogueira, D., Coqueugniot, H., Santos, F., Tillier, A.-m, 2021. The bony labyrinth of Qafzeh 25 *Homo sapiens* from Israel. Archaeol. Anthropol. Sci. https://doi.org/10.1007/s12520-021-01377-2.

Debenath, A., 1976. La Grotte de Dar-es-Soltane II à Rabat (Maroc). Géologie et préhistoire. Bulletins et Mémoires de la Société d'anthropologie de Paris. XIII° Série. Tome 3 Fasc. 2, 181–182.

Dutailly, B., Coqueugniot, H., Desbarats, P., Gueorguieva, S., Synave, R., 2009. 3D surface reconstruction using HMH algorithm. *Proceedings of the 16th IEEE International Conference on Image Processing*, 2505–2508.

Dutour, O., 2011. *La paléopathologie*, Éditions du CTHS, Paris, 170p.

Ferembach, D., 1976. Les restes humains de la Grotte de Dar-es-Soltane II (Maroc). Campagne 1975. Bulletins et Mémoires de la Société d'anthropologie de Paris. XIII° Série. Tome 3 Fasc. 2, 183–193.

Gómez-Olivencia, A., Crevecoeur, I., Balzeau, A., 2015. La Ferrassie 8 Neandertal child reloaded: new remains and re-assessment of the original collection. J. Hum. Evol. 82, 107–126.

Harvati, K., Hublin, J.J., 2012. Morphological continuity of the face in the late Middle and Late Pleistocene hominins from northwestern Africa – A 3D geometric morphometric analysis. In: Hublin, J.J., McPherron, S. (Eds.), Modern Origins: A North African Perspective. Springer, *Dordrecht*, pp. *179–188*.

Hill, C.A., Radovčić, J., Frayer, D.W., 2014. Brief communication: investigation of the semicircular canal variation in the Krapina Neandertals. Am. J. Phys. Anthropol. 154, 302–306.

Huang, B.Y., Zdanski, C., Castillo, M., 2012. Pediatric sensorineural hearing loss, part 2: syndromic and acquired causes. Am. J. Neuroradiol. 33 (3), 399–406. https://doi.org/10.3174/ajnr.A2499.

Hublin, J.J., Spoor, F., Braun, M., Zonneveld, F., Condemi, S., 1996. A late Neanderthal associated with upper paleolithic artefacts. Nature 381, 224–226.

Kaplan, S.L., Catlin, F.I., Weaver, T., Feigin, R.D., 1984. Onset of hearing loss in children with bacterial meningitis. Pediatrics 73 (5), 575–578. https://doi.org/10.1542/peds.73.5.575.

Larson, C., Jorgensen, S.A., Towbin, A.J., Towbin, R., 2016. Labyrinthine ossificans. Appl. Radio. 45 (11), 40–41.

Ortner, D.J., 2003. Identification of Pathological Conditions in Human Skeletal Remains, 645. Academic Press. https://doi.org/10.1016/B978-0-12-528628-2.X5037-6.

Ozgen, B., Oguz, K.K., Atas, A., Sennaroglu, L., 2009. Complete labyrinthine aplasia: clinical and radiologic findings with review of the literature. AJNR Am. J. Neuroradiol. 30 (4), 774–780. https://doi.org/10.3174/ajnr.A1426.

Paparella, M.M., Sugiura, S., 1967. The pathology of suppurative labyrinthitis. Ann. Otol. Rhinol. Laryngol. 76 (3), 554–586.

Purohit, B., Hermans, R., Op de Beeck, K., 2014. Imaging in otosclerosis: a pictorial review. Insights Imaging 5 (2), 245–252. https://doi.org/10.1007/s13244-014-0313-9.

Raynal, J.-P., Occhietti, S., 2012. Amino-chronology and an earlier age for the Aterian. In: Hublin, J.J., McPherron, S. (Eds.), Modern Origins: A North African Perspective. Springer, Dordrecht.

Sanghan, N., Chansakul, T., Kozin, E.D., Juliano, A.F., Curtin, H.D., Reinshagen, K.L., 2018. Retrospective review of otic capsule contour and thickness in patients with otosclerosis and individuals with normal hearing on CT. Am. J. Neuroradiol. 39 (12), 2350–2355. https://doi.org/10.3174/ajnr.A5892.

Schwenninger, J.L., Collcutt, S.N., Barton, N., Bouzouggar, A., Clark-Balzan, L., El Hajraoui, M.A., Nespoulet, R., Debénat, A., 2010. A new luminescence chronology for Aterian cave sites on the Atlantic coast of Morocco. In: Garcea, E.A.A. (Ed.), South-Eastern Mediterranean Peoples between 130,000 and 10,000 years ago. Oxbow Books, Oxford, pp. 18–36.

Spoor, F., 1993. *The Comparative Morphology and Phylogeny Of The Human Bony Labyrinth*, Ph.D. Dissertation, Utrecht University.

Spoor, F., Hublin, J.-J., Braun, M., Zonneveld, F., 2003. The bony labyrinth of Neanderthals. J. Hum. Evol. 44, 141–165.

Swartz, J.D., Mandell, D.M., Faerber, E.N., Popky, G.L., Ardito, J.M., Steinberg, S.B., Rojer, C.L., 1985. Labyrinthine ossification: etiologies and CT findings. Radiology 157 (2), 395–398.

Swartz, J.D. , Mukherji, S.K. , 2009. The Inner Ear and Otodystrophies. In: Swartz J.D. , Loevner L.A. , eds. Imaging of the Temporal Bone. 4. New York: Thieme; pp. 298–411.

Taxak, P., Ram, C., 2020. Labyrinthitis and labyrinthitis ossificans - A case report and review of the literature. J. Radio. Case Rep. 14 (5), 1–6. https://doi.org/10.3941/jrcr.v14i5.3706.