

## Alterations of gray and white matter morphology in obsessive compulsive disorder

Oscar F. Gonçalves<sup>1</sup>, Sonia Sousa<sup>1</sup>, Sandra Carvalho<sup>1</sup>, Jorge Leite<sup>1</sup>, Ana Ganho<sup>1</sup>, Ana Fernandes-Gonçalves<sup>2</sup>, Fernando Pocinho<sup>3</sup>, Angel Carracedo<sup>4</sup> and Adriana Sampaio<sup>1</sup>

<sup>1</sup> University of Minho, <sup>2</sup> Cuf Hospital, <sup>3</sup> University of Coimbra, and <sup>4</sup> University of Santiago de Compostela

### Abstract

**Background:** While the ethio-pathogenesis of Obsessive-Compulsive disorder (OCD) remains unknown, there is increased evidence of widespread structural alterations in both white and gray matter in OCD patients that include, but are not restricted, to abnormalities in cortico-striatal-thalamo-cortical (CSTC) regions. The objective of this study was to test the existence of structural alterations in both white and gray matter in a sample of OCD patients when compared with a group of non-clinical matched controls (NCC), using voxel-based morphometry (VBM). **Method:** Fifteen patients with OCD and 15 NCC underwent MRI structural scanning. **Results:** Frontal (increased gray matter in the middle frontal gyrus) and subcortical regions (increased white matter in the pallidum) were found to be affected in patients. Additionally, temporal-parietal regions were also found to be affected and highly correlated with OCD symptom severity (decrease of gray matter in the superior parietal lobe and white matter in the angular and superior temporal gyri). **Conclusions:** These alterations may be associated with prominent OCD symptoms, such as difficulties with inhibitory control (pallidum, angular gyrus), executive functioning (middle frontal gyris), compulsive checking (superior temporal gyrus) and visual-spatial deficits (superior parietal lobe).

**Keywords:** Obsessive-compulsive disorder, gray matter, white matter, voxel based morphometry.

### Resumen

**Las alteraciones de morfología de la sustancia blanca y gris en el trastorno obsesivo compulsivo. Antecedentes:** mientras que la etiopatogenia del trastorno obsesivo-compulsivo (TOC) sigue siendo desconocida, hay una mayor evidencia en las personas que sufren este trastorno de alteraciones estructurales que incluyen, pero no se limitan, a anomalías en regiones cortico-estriado-tálamo-corticales (CSTC). El objetivo de este estudio fue comprobar la existencia de alteraciones estructurales tanto en la materia blanca como en la materia gris en una muestra de pacientes con TOC en comparación con un grupo de controles no clínicos (NCC), utilizándose para ello análisis morfométricos basados en "voxel" (VBM). **Método:** quince pacientes con TOC y quince NCC fueron estudiados mediante resonancia magnética estructural. **Resultados:** se encontraron alteraciones en los pacientes en regiones frontales (aumento de la materia gris en la circunvolución frontal media) y subcorticales (aumento de la materia blanca en el pallidum). Además, también se encontraron afectadas regiones temporo-parietales con una alta correlación con la gravedad de los síntomas del TOC (disminución de la materia gris en el lóbulo parietal superior y de la materia blanca en las circunvoluciones temporales angular y superior). **Conclusiones:** las alteraciones encontradas pueden estar asociadas con síntomas predominantes en el TOC, como dificultades en el control inhibitorio (pallidum, giro angular), función ejecutiva (circunvolución frontal media), verificaciones compulsivas (circunvolución temporal superior) y déficit visual-espacial (lóbulo parietal superior).

**Palabras clave:** trastorno obsesivo compulsivo, materia blanca, materia gris, morfometría basada en voxel.

While the ethio-pathogenesis of OCD is still being disputed, there is some consensus on the evidence of structural abnormalities in regions associated with cortico-striatal-thalamo-cortical loops (CSTC) (Radua, van den Heuvel, Surguladze, & Mataix-Cols, 2010). These alterations are thought to be associated with failures in the main inhibitory processes at the cognitive and behavior

levels (van Velzen, Vriend, de Wit, & van den Heuvel, 2014) and to account for the core OCD symptoms characterized by difficulties in inhibiting intrusive thoughts or images (i.e., obsessions) and/or ritualized behaviors (i.e., compulsions).

Initial meta-analyses on volumetric alterations of gray matter in OCD confirmed evidence for decreases in several frontal regions (e.g., left anterior cingulate, bilateral orbitofrontal) and increases in subcortical regions (e.g. thalamus, caudate putamen) (Rotge et al., 2009). However, more recent meta-analyses extended these findings to regions outside the frontal-subcortical areas, including alterations of gray matter density in the superior parietal lobe (Peng et al., 2012; Radua & Mataix-Cols, 2009) supramarginal gyrus (Rotge et al., 2010), and cerebellum (de Wit et al., 2014). A recent

review of voxel-based morphometry studies by Piras et al. (2015) confirmed evidence for widespread gray matter alterations beyond the typical frontal-subcortical regions and including volumetric changes in the temporal, parietal and occipital regions.

Correlative abnormalities with white matter volumes have been identified in OCD. Consistent with initial studies with gray matter alterations in OCD, Duran, Hoexter, Valente, Miguel, and Busatto (2009) reported that an increased white matter volume in the bilateral anterior limb of the internal capsule is associated with symptomatic OCD severity. However, a more recent meta-analysis by Radua et al. (2014) showed that OCD patients have a significant white matter increase in the corpus callosum, cingulum bundle, right anterior thalamic radiation and left arcuate fasciculus, along with decreases in the right superior longitudinal fasciculus, cortico-spinal tract, frontal aslant tract and anterior body of the corpus callosum. Consistently, a VBM study by Park and Jeong (2015) confirmed white matter increases for OCD in extended brain regions such as the right dorsolateral prefrontal cortex, middle frontal gyrus, precuneus, and inferior parietal lobe.

Summing up, there is increased evidence of widespread structural alterations in both white and gray matter in OCD patients that include, but are not restricted to, abnormalities in CSTC regions. The existence of widespread abnormalities in gray and white matter may help to explain the diversity of symptoms in OCD that go well beyond difficulties in inhibitory control (Gonçalves, Sousa et al., 2015) to include difficulties in emotional processing (Gonçalves, Soares et al., 2015) and memory (Olson et al., 2016).

The objective of this study is to test the existence of structural alterations in both white and gray matter in a sample of OCD patients when compared with a group of non-clinical matched controls using VBM.

## Methods

### Participants

Fifteen patients with OCD (11 men, 4 women) and 15 non-clinical controls (NCC) (9 men, 6 women), matched by age and education were enrolled in the present study. All participants gave their written informed consent prior to their inclusion in the study. The study was performed in accordance with the Declaration of Helsinki. The demographic and clinical data are presented in table 1. OCD and NCC groups did not differ significantly in terms of

age  $t(28) = .44, p > .06$ , years of education  $t(28) = -.35, p > .05$  and right-handedness  $t(28) = .71, p > .05$ . As expected, the YBOCS and BDI scores were higher in the OCD group  $t(28) = 12.81, p < .001$  and  $t(28) = 3.60, p < .001$ , respectively. Depression scores were below cutoff values for both groups. Participants were assessed with the Edinburgh Handedness Inventory (EHI) (Oldfield, 1971), the Structural Clinical Interview for Diagnostic and Statistical Manual of Mental Disorders (SCID-I) (First, Spitzer, Gibbon, & Williams, 1996), the Yale-Brown Obsessive Compulsive Scale (YBOCS) (Goodman et al., 1989) and the Beck Depression Inventory (BDI) (Beck, Steer, & Carbin, 1988). OCD patients were in stable treatment and none was diagnosed with comorbid conditions. The NCC group did not present history of mental disorders, psychiatry medication or drug abuse.

### Procedure

#### Image data acquisition

Within one week of the clinical assessment, participants underwent the scanning procedure in a clinically approved Siemens Magnetom TrioTim 3T (Siemens Medical Solutions, Erlangen, Germany) with a 32-channel head coil. A T1 high-resolution anatomical sequence (i.e. 3D MPRAGE, magnetization prepared rapid gradient echo) was performed with the following scan parameters: repetition time (TR) = 2.3 s, echo time (TE) = 2.98 ms, 160 sagittal slices with no gap, Field-of-View (FoV) = 256 mm, flip angle (FA) = 9°, in-plane resolution = 1 × 1 mm<sup>2</sup> and slice thickness = 1mm.

#### Voxel based morphometry (VBM)

VBM is an automated whole brain processing method, which allows the composition of brain tissue to be compared among (between and/or within) groups (Ashburner & Friston, 2000) being an indirect measure of volume. Before beginning processing, all images were visually inspected to confirm that they had not been affected by critical head motion and that participants had no brain lesions. Data were processed using SPM12 pre-processing pipeline and statistical tools (Wellcome Trust Centre for Neuroimaging, University College London, UK; <http://www.fil.ion.ucl.ac.uk/spm/>) executed in Matlab R2011a (MathWorks, Natick, MA). The anatomical images were first manually reoriented to the ICBM 152 average SPM template in Montreal Neurological Institute (MNI) space. Next, images were segmented into gray matter, white matter and cerebrospinal fluid using an extension of the standard unified segmentation model in SPM12. White and gray matter were co-registered across participants using the DARTEL (Diffeomorphic Anatomical Registration Through Exponentiated Lie Algebra) algorithm (Ashburner & Friston, 2000; Ashburner, 2007) to improve registration. Images were then smoothed with an 8 mm FWHM Gaussian filter to reduce possible error from between-subject variability in local anatomy and to improve the normality of the data.

### Data analysis

Two-sample t-tests were performed to analyze regional volume differences between OCD and NCC groups. GM and WM images were assessed separately and 2 contrasts were set. Four independent t tests were performed (GM/WM: NCC>OCD/NCC<OCD). SPM maps were generated for between group differences in brain areas

Table 1

Demographic data by group; \*\*\*  $p < .001$ ; \*\*  $p < .01$ ; OCD = Obsessive-Compulsive Disorder; NCC=Non Clinical Controls

	OCD N = 15 Mean (SD)	NCC N = 15 Mean (SD)	t (28)
% Male	73.3	60	
% Female	26.7	40	
% Caucasian	100	100	
Age	31.67 (11.44)	30.07 (8.22)	.44
Education	13 (3.55)	13.04 (2.75)	-.35
Handedness (EHI)	93.53 (7.85)	92.00 (13.73)	.71
Y-BOCS	22.73 (6.62)	.53 (1.13)	12.81***
BDI <sup>a</sup>	9.40 (6.65)	2.53 (3.23)	3.60***

where GM and WM volumes were significantly lower/higher in OCD than in NCC. The threshold masking was set to an absolute of .2 in order to exclude from the analysis tissue-related voxels. For statistical threshold criteria we accepted a  $p < .001$  uncorrected multi comparisons with a minimum of 20 voxels (Yoo et al, 2008). Anatomical localization was performed using the aal.nii atlas as inclusive to extract regions with statistical significance and corresponding labels were obtained using MRICron toolbox.

Regions found to have significant volumetric alterations in OCD were correlated with YBOCS scores using Pearson's correlations.

## Results

### Total gray and white matter in OCD and NCC

Table 2 shows the total volumes for gray and white matter. As can be seen no significant differences were found between OCD and NCC in the total gray  $t(28) = -1.13, p = .266$  or white matter volumes  $t(28) = -.46, p = .643$ .

### Regional gray and white matter differences between OCD and NCC

Table 3 and Figures 1 and 2 show the regions in which significant gray and white matter differences were found between OCD and NCC. OCD patients showed, when compared with NCC, a significant decrease in gray matter volume of the left superior parietal lobe  $t(28) = 3.96, p < .0001$  contrasting with a significant increase of gray matter in the right middle frontal gyrus  $t(28) = 4.14, p < .0001$ .

Significant decreased white matter volumes was found in the right angular gyrus  $t(28) = 4.35, p < .0001$  and in the right superior

temporal gyrus  $t(28) = 3.93, p < .0001$ . Contrastingly, significant white matter volume increases were found for the OCD patients in the right pallidum  $t(28) = 3.75, p < .0001$ .

### Correlations between selected regions and severity scores

Significant positive correlations were found between YBOCS severity scores and middle frontal gray matter  $r(28) = .36, p < .05$  and right pallidum white matter  $r(28) = .40, p < .05$ . Significantly negative correlations were found between YBOCS scores and left superior parietal lobe gray matter  $r(28) = -.68, p < .001$ , right angular gyrus white matter  $r(28) = -.60, p < .001$ , and right superior temporal gyrus white matter volumes  $r(28) = -.61, p < .001$ .

## Discussion

The objective of this study was to test the existence of structural neuroanatomical differences in OCD patients when compared with NCC, as measured by VBM. Overall, no differences were found between OCD and NCC in total gray and white matter volumes. In terms of regional differences, OCD patients showed significantly decreased gray matter in the left superior parietal lobe and increased gray matter in the right middle frontal gyrus. Regarding white matter, there was a significant decrease in white matter in the right angular and the right superior temporal gyri, along with a significant volumetric increase in the right pallidum. All these regional alterations were significantly correlated with severity scores.

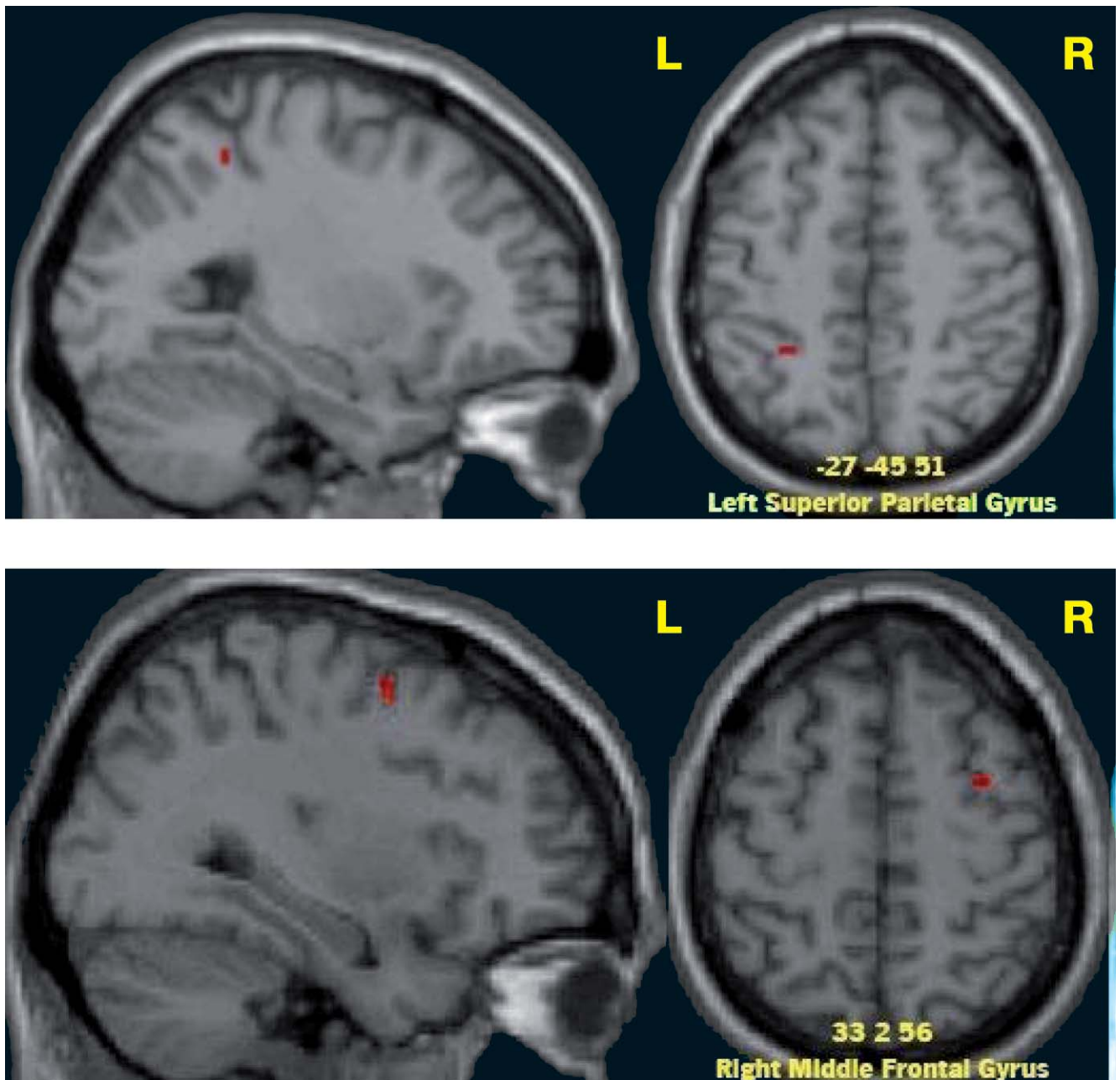
The lack of differences in total white and gray matter volumes is consistent with previous studies. For example, a recent study by Park and Jeong (2015) in a similar VBM study, did not report significant differences in intracranial volumes between OCD and healthy controls. Several meta-analyses confirm the result of unaltered total gray (Radua & Mataix-Cols, 2009) and white matter volumes in OCD patients (Rotge et al., 2009).

The finding of increased gray matter in the right middle frontal gyrus contrasts with opposite findings by other authors. For example, Togao et al. (2010) reported a decrease in gray matter volume in the middle frontal gyrus in OCD. However, Christian et al. (2008) found a result that is consistent with our data by showing a volumetric increase in the middle frontal gyrus for non-depressed OCD patients. Consistently, a more recent meta-analysis by Eng,

	Gray matter			White matter		
	Mean (SD) ml/cm <sup>3</sup>	t value (28)	p value	Mean (SD) ml/cm <sup>3</sup>	t value (28)	p value
OCD	788 (131)	-1.136	.266	376 (83)	.468	.643
NCC	743 (80)			392 (102)		

Anatomical label	Direction of difference	MNI Coordinates <sup>a</sup> x y z	Cluster size (K <sub>v</sub> )	Peak t score	p value <sup>b</sup>
<b>Gray matter</b>					
Parietal_Superior_(Left)	Decreased in OCD	-27 -45 51	24	3.96	<.0001
Frontal_Middle Gyrus_(Right)	Increased in OCD	33 2 56	39	4.14	<.0001
<b>White matter</b>					
Angular Gyrus (Right)	Decreased in OCD	33 -57 51	91	4.35	<.0001
Superior Temporal_Gyrus (Right)	Decreased in OCD	56 -6 0	46	3.93	<.0001
Pallidum_(Right)	Increased in OCD	17 6 0	122	3.75	<.0001

<sup>a</sup> Montreal Neurological Institute coordinates of the voxel of maximal statistical significance within each region  
<sup>b</sup> Statistical significance set to  $p < .001$ , uncorrected for multiple comparisons at voxel level



**Figure 1.** Regional differences in gray matter (R-Right hemisphere; L- Left Hemisphere)

Sim, and Chen (2015) reported evidence of increased volume in the right middle frontal gyrus in OCD. The altered volume in this region may be associated with the executive impairments often present in OCD symptomatology (Snyder, Kaiser, Warren, & Heller, 2015). Patterns of hyperactivation (Gonçalves, Soares et al., 2015) and hyperconnectivity in this region (Glahn, Prell, Grosskreutz, Peschel, & Müller-Vahl, 2015; Park & Jeong, 2015) were described in OCD patients.

Alterations of gray matter in parietal regions were repeatedly found, even though with inconsistent findings across parietal regions. For example, while Radua and Mataix-Cols (2009) and Peng et al. (2012) reported an increase in the right superior parietal lobe, Rotge et al. (2010) mention a decrease in the supramarginal

gyrus and Eng et al. (2015) a decrease in the postcentral gyrus and inferior parietal lobe.

Consistent with our finding of a decreased volume in the left superior parietal lobe gray matter, Jayarajan et al. (2015) reported that the volume of the superior parietal lobe was negatively correlated with OCD severity. According to Piras et al. (2015) recent review, the decrease in the parietal gray matter is now a robust finding and can be partially associated not only with the visual-spatial processing deficits found in OCD patients (Kim et al., 2008) but also with an impaired fronto-parietal cognitive control network (Cole, Repovš, & Anticevic, 2014).

Interestingly, a decrease in white matter was also found in our OCD patients in two temporo-parietal regions: the right angular

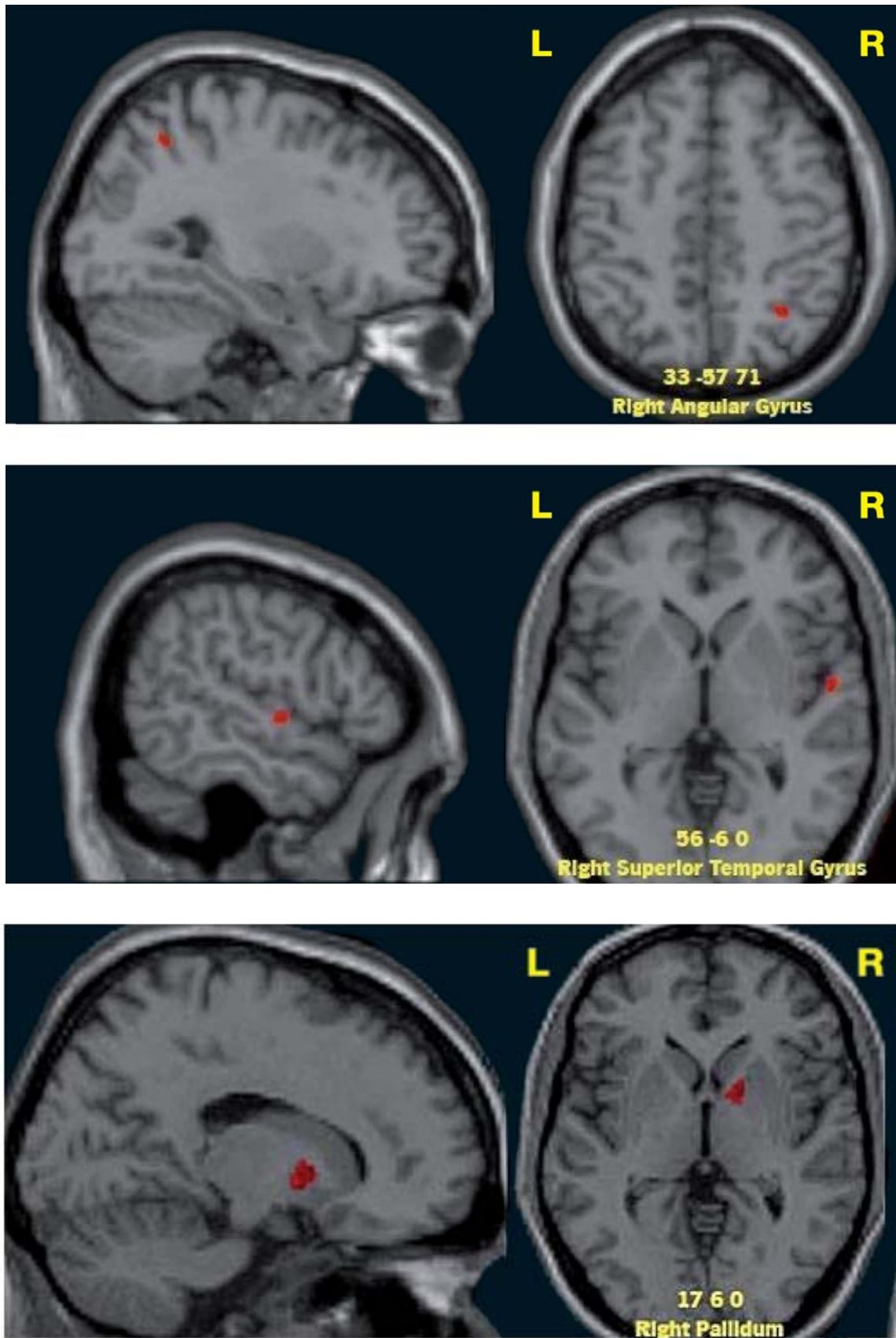


Figure 2. Regional differences in white matter (R-Right hemisphere; L- Left Hemisphere)

gyrus and the right superior temporal gyrus. The angular gyrus is a converging region of the inferior posterior parietal lobe interconnecting the temporal, parietal and occipital cortices and is seen as an integrative hub for multiple psychological processes (Seghier, 2013). A study by Wager et al. (2005) showed the role of the right angular gyrus in a go-no-go response inhibition task, a task where OCD patients perform poorly (van Velzen et al., 2014). Curiously, a VBM study by Park and Jeong (2015) found a volumetric increase in the inferior parietal lobe but in the left hemisphere while no significant differences were found between OCD and healthy controls for the right hemisphere. A review of white matter diffusion studies by (Piras, Piras, Caltagirone, & Spalletta, 2013) reported hyperconnectivity in fasciculi connecting frontal with inferior parietal cortices (e.g., superior longitudinal fasciculus; inferior longitudinal fasciculus).

Equally interesting is the finding of decreased volumetry for the OCD group in the right superior temporal gyrus. A previous study by Gonçalves, Soares, et al. (2015) found increased activation of this region when OCD patients are confronted with threatening stimuli. Rotge et al. (2008) found similar results using a symptom provocation paradigm while van den Heuvel et al. (2009) found that 'harm/checking' scores in YBOCS were negatively correlated with white matter volumes in the right temporal lobe. Worth noting that patients with temporal lobe disorders frequently exhibit compulsive behaviors similar to those presented in OCD conditions (c.f., Rosso et al., 2001).

The OCD increased white matter density in the pallidum region is consistent with previous volumetric and connectivity studies (Yoo et al., 2008). Globus pallidus is surrounded by white matter fibers from the internal capsula and is part of the basal ganglia with a major role in motor and non motor inhibitory regulation (Jahanshahi, Obeso, Rothwell, & Obeso, 2015). Basal ganglia structural abnormalities are among the most consistent findings in the OCD research literature pointing to the existence of an increased connectivity (Lochner et al., 2012) and hyperactivity in basal ganglia regions (Banca et al., 2015). The consistent finding of basal ganglia alterations in OCD, explains why several of these regions (including the anterior limb of the internal capsula) have been used as targets for deep brain stimulation in refractory OCD spectrum disorders (van Westen, Rietveld, Figeo, & Denys, 2015).

Several previous studies reported an association between volumetric alterations and severity of OCD symptoms (Fontenelle et al., 2009; Piras et al., 2015). In our study it is particularly evident the existence of negative correlations between YBOCS scores with gray (left superior parietal lobe) and white matter (right angular and superior temporal gyri) volumes in temporal-parietal regions. Other studies reported similar negative correlations between symptom severity and gray matter in the supramarginal gyrus (Koprivová et al., 2009), postcentral and superior temporal gyri (Yoo et al., 2008), or left superior parietal lobe (Jayarajan et al., 2015). Also a magnetic resonance spectroscopy study by Kitamura et al. (2006) reported that alterations in parietal white matter were positively correlated with OCD severity.

Despite the consistency in the current findings they should be regarded cautiously in light of several methodological limitations.

Due to sample size limitations, these results must be seen as preliminary. Future studies with larger sample sizes should use more conservative corrections in order to avoid chances of type I error. Additionally, as it has been demonstrated, OCD is a heterogeneous disorder and the inconsistent findings may be associated with specific characteristics of a given sample. This is well illustrated in a recent study by Subirà et al. (2015) showing that, in a large sample of OCD patients, those with sensory phenomenon symptoms (i.e., uncomfortable bodily sensations preceding or accompanying repetitive rituals) had an increased gray matter volume in bilateral medial sensorimotor cortex, when compared with those without these symptoms.

Lastly, the level of depression, which is significantly higher in the OCD group might have contributed to the volumetric differences found between groups. Nonetheless, volumetric differences related to mood disorders are more commonly reported over the orbitofrontal cortex, the anterior cingulate, as well as in striatum, amygdala and hippocampus (Konarski et al., 2008). In the present study, none of these areas were found to be significantly altered in OCD patients. Thus, the contribution of depression symptoms to the present results, although possible, is highly unlikely.

Concluding, the present study confirms widespread volumetric alterations in both gray and white matter regions in OCD. Traditional regions from frontal (decreased gray matter in the middle frontal gyrus) and subcortical regions (increase white matter in the pallidum) were found to be affected in patients. Additionally, temporal-parietal regions were also found to be affected and highly correlated with OCD symptom severity (decrease of gray matter in the superior parietal lobe and white matter in the angular and superior temporal gyri). These alterations may be associated with prominent symptoms in OCD, such as difficulties with inhibitory control (pallidum, angular gyrus), executive functioning (middle frontal gyrus), compulsive checking (superior temporal gyrus) and visual-spatial deficits (superior parietal lobe). Thus future studies should assess the usefulness of these findings to target patient and/or symptom tailored interventions in order to maximize clinical efficacy, or eventually as a predictor of treatment response.

#### Acknowledgments

Óscar F. Gonçalves was funded by the Brazilian National Council for Scientific and Technological Development (CNPq) as a Special Visiting Researcher of the Science Without Borders program (grant number: 401143/2014-7). This study was partially conducted at the Neuropsychophysiology Lab from the Psychology Research Centre (UID/PSI/01662/2013), University of Minho, and supported by the Portuguese Foundation for Science and Technology and the Portuguese Ministry of Science, Technology and Higher Education through national funds and co-financed by FEDER through COMPETE2020 under the PT2020 Partnership Agreement (POCI-01-0145-FEDER-007653). This work was also supported by the Portuguese Foundation for Science and Technology (FCT) and European Union (FSE-POPH) with two individual grants (SFRH/BPD/86041/2012 and SFRH/BPD/86027/2012).

## References

- Ashburner, J. (2007). A fast diffeomorphic image registration algorithm. *NeuroImage*, 38(1), 95-113.
- Ashburner, J., & Friston, K. J. (2000). Voxel-based morphometry-the methods. *NeuroImage*, 11(6 Pt 1), 805-821.
- Banca, P., Voon, V., Vestergaard, M. D., Philippiak, G., Almeida, I., Pochinho, F., ..., Castelo-Branco, M. (2015). Imbalance in habitual versus goal directed neural systems during symptom provocation in obsessive-compulsive disorder. *Brain*, 138(Pt 3), 798-811.
- Beck, A. T., Steer, R. A., & Carbin, M. G. (1988). Psychometric properties of the Beck Depression Inventory: Twenty-five years of evaluation. *Clinical Psychology Review*, 8, 77-100.
- Christian, C. J., Lencz, T., Robinson, D. G., Burdick, K. E., Ashtari, M., Malhotra, A. K., ..., Szeszko, P. R. (2008). Gray matter structural alterations in obsessive-compulsive disorder: Relationship to neuropsychological functions. *Psychiatry Research - Neuroimaging*, 164(2), 123-131.
- Cole, M. W., Repovš, G., & Anticevic, A. (2014). The frontoparietal control system: A central role in mental health. *The Neuroscientist*, 20(6), 652-664.
- de Wit, S. J., Alonso, P., Schweren, L., Mataix-Cols, D., Lochner, C., Menchón, J. M., ..., van den Heuvel, O. A. (2014). Multicenter voxel-based morphometry mega-analysis of structural brain scans in obsessive-compulsive disorder. *The American Journal of Psychiatry*, 171(3), 340-349.
- Duran, F. L. de S., Hoexter, M. Q., Valente, A. A., Miguel, E. C., & Busatto, G. F. (2009). Association between symptom severity and internal capsule volume in obsessive-compulsive disorder. *Neuroscience Letters*, 452(1), 68-71.
- Eng, G. K., Sim, K., & Chen, S.-H. A. (2015). Meta-analytic investigations of structural grey matter, executive domain-related functional activations, and white matter diffusivity in obsessive compulsive disorder: An integrative review. *Neuroscience and Biobehavioral Reviews*, 52, 233-257.
- First, M. B., Spitzer, L. R., Gibbon, M., & Williams, J. B. W. (1996). *Structured Clinical Interview for DSM-IV Axis I Disorders, Clinician Version (SCID-CV)*. Washington, D.C.: American Psychiatry Press.
- Fontenelle, L. F., Harrison, B. J., Yücel, M., Pujol, J., Fujiwara, H., & Pantelis, C. (2009). Is there evidence of brain white-matter abnormalities in obsessive-compulsive disorder?: A narrative review. *Topics in Magnetic Resonance Imaging*, 20(5), 291-298.
- Glahn, A., Prell, T., Grossekreutz, J., Peschel, T., & Müller-Vahl, K. R. (2015). Obsessive-compulsive disorder is a heterogeneous disorder: Evidence from diffusion tensor imaging and magnetization transfer imaging. *BMC Psychiatry*, 15(1), 135.
- Gonçalves, Ó. F., Soares, J. M., Carvalho, S., Leite, J., Ganho, A., Fernandes-Gonçalves, A., ..., Sampaio, A. (2015). Brain activation of the defensive and appetitive survival systems in obsessive compulsive disorder. *Brain Imaging and Behavior*, 9(2), 255-263.
- Gonçalves, Ó. F., Sousa, S., Maia, L., Carvalho, S., Leite, J., Ganho, A., ..., Sampaio, A. (2015). Inferior frontal gyrus white matter abnormalities in obsessive-compulsive disorder. *NeuroReport*, 26(9), 495-500.
- Goodman, W. K., Price, L. H., Rasmussen, S. A., Mazure, C., Fleischmann, R. L., Hill, C. L., ..., Charney, D. S. (1989). The Yale-Brown Obsessive Compulsive Scale. I. Development, use, and reliability. *Archives of General Psychiatry*, 46, 1006-1011.
- Jahanshahi, M., Obeso, I., Rothwell, J. C., & Obeso, J. A. (2015). A fronto-striato-subthalamic-pallidal network for goal-directed and habitual inhibition. *Nature Reviews. Neuroscience*, 16(12), 719-732.
- Jayarajan, R. N., Agarwal, S. M., Viswanath, B., Kalmady, S. V., Venkatasubramanian, G., Srinath, S., ..., Janardhan Reddy, Y. C. (2015). A Voxel Based Morphometry Study of Brain Gray Matter Volumes in Juvenile Obsessive Compulsive Disorder. *Journal of the Canadian Academy of Child and Adolescent Psychiatry = Journal de l'Académie Canadienne de Psychiatrie de L'enfant et de L'adolescent*, 24(2), 84-91.
- Kim, J., Blake, R., Park, S., Shin, Y. W., Kang, D. H., & Kwon, J. S. (2008). Selective impairment in visual perception of biological motion in obsessive-compulsive disorder. *Depression and Anxiety*, 25(7), E15-25.
- Kitamura, H., Shioiri, T., Kimura, T., Ohkubo, M., Nakada, T., & Someya, T. (2006). Parietal white matter abnormalities in obsessive-compulsive disorder: A magnetic resonance spectroscopy study at 3-Tesla. *Acta Psychiatrica Scandinavica*, 114(2), 101-108.
- Konarski, J. Z., McIntyre, R. S., Kennedy, S. H., Rafi-Tari, S., Soczynska, J. K., & Ketter, T. A. (2008). Volumetric neuroimaging investigations in mood disorders: Bipolar disorder versus major depressive disorder. *Bipolar Disorders*, 10(1), 1-37.
- Koprivová, J., Horáček, J., Tintera, J., Prasko, J., Raszka, M., Ibrahim, I., & Höschl, C. (2009). Medial frontal and dorsal cortical morphometric abnormalities are related to obsessive-compulsive disorder. *Neuroscience Letters*, 464(1), 62-66.
- Lochner, C., Fouché, J.-P., du Plessis, S., Spottiswoode, B., Seedat, S., Fineberg, N., ..., Stein, D. J. (2012). Evidence for fractional anisotropy and mean diffusivity white matter abnormalities in the internal capsule and cingulum in patients with obsessive-compulsive disorder. *Journal of Psychiatry & Neuroscience*, 37(3), 193-199.
- Olson, C. A., Hale, L. R., Hamilton, N., Powell, J. N., Martin, L. E., & Savage, C. R. (2016). Altered source memory retrieval is associated with pathological doubt in obsessive-compulsive disorder. *Behavioural Brain Research*, 296, 53-60.
- Park, S.-E., & Jeong, G.-W. (2015). Cerebral white matter volume changes in patients with obsessive-compulsive disorder: Voxel-based morphometry. *Psychiatry and Clinical Neurosciences*, 69(11), 717-723.
- Peng, Z.-W., Lui, S. S. Y., Cheung, E. F. C., Jin, Z., Miao, G. D., Jing, J., & Chan, R. C. K. (2012). Brain structural abnormalities in obsessive-compulsive disorder: Converging evidence from white matter and grey matter. *Asian Journal of Psychiatry*, 5(4), 290-296.
- Piras, F., Piras, F., Caltagirone, C., & Spalletta, G. (2013). Brain circuitries of obsessive compulsive disorder: A systematic review and meta-analysis of diffusion tensor imaging studies. *Neuroscience and Biobehavioral Reviews*, 37(10 Pt 2), 2856-2877.
- Piras, F., Piras, F., Chiapponi, C., Girardi, P., Caltagirone, C., & Spalletta, G. (2015). Widespread structural brain changes in OCD: A systematic review of voxel-based morphometry studies. *Cortex*, 62, 89-108.
- Radua, J., Grau, M., van den Heuvel, O. A., Thiebaut de Schotten, M., Stein, D. J., Canales-Rodríguez, E. J., ..., Mataix-Cols, D. (2014). Multimodal voxel-based meta-analysis of white matter abnormalities in obsessive-compulsive disorder. *Neuropsychopharmacology*, 39(7), 1547-1557.
- Radua, J., & Mataix-Cols, D. (2009). Voxel-wise meta-analysis of grey matter changes in obsessive-compulsive disorder. *British Journal of Psychiatry*, 195(5), 393-402.
- Radua, J., van den Heuvel, O. A., Surguladze, S., & Mataix-Cols, D. (2010). Meta-analytical comparison of voxel-based morphometry studies in obsessive-compulsive disorder vs other anxiety disorders. *Archives of General Psychiatry*, 67(7), 701-711.
- Rosso, S. M., Roks, G., Stevens, M., de Koning, I., Tanghe, H. L. J., Kamphorst, W., ..., van Swieten, J. C. (2001). Complex compulsive behaviour in the temporal variant of frontotemporal dementia. *Journal of Neurology*, 248(11), 965-970.
- Rotge, J.-Y., Guehl, D., Dilharreguy, B., Cuny, E., Tignol, J., Bioulac, B., ..., Aouizerate, B. (2008). Provocation of obsessive-compulsive symptoms: A quantitative voxel-based meta-analysis of functional neuroimaging studies. *Journal of Psychiatry & Neuroscience*, 33(5), 405-412.
- Rotge, J.-Y., Guehl, D., Dilharreguy, B., Tignol, J., Bioulac, B., Allard, M., ..., Aouizerate, B. (2009). Meta-analysis of brain volume changes in obsessive-compulsive disorder. *Biological Psychiatry*, 65(1), 75-83.
- Rotge, J.-Y., Langbour, N., Guehl, D., Bioulac, B., Jaafari, N., Allard, M., ..., Burbaud, P. (2010). Gray matter alterations in obsessive-compulsive disorder: An anatomic likelihood estimation meta-analysis. *Neuropsychopharmacology*, 35(3), 686-691.
- Seghier, M. L. (2013). The angular gyrus: multiple functions and multiple subdivisions. *The Neuroscientist*, 19(1), 43-61.
- Snyder, H. R., Kaiser, R. H., Warren, S. L., & Heller, W. (2015). Obsessive-compulsive disorder is associated with broad impairments in executive function: A meta-analysis. *Clinical Psychological Science*, 3(2), 301-330.

- Subirà, M., Sato, J. R., Alonso, P., do Rosário, M. C., Segalàs, C., Batistuzzo, M. C., ..., Soriano-Mas, C. (2015). Brain structural correlates of sensory phenomena in patients with obsessive-compulsive disorder. *Journal of Psychiatry & Neuroscience*, 40(4), 232-240.
- Togao, O., Yoshiura, T., Nakao, T., Nabeyama, M., Sanematsu, H., Nakagawa, A., ..., Honda, H. (2010). Regional gray and white matter volume abnormalities in obsessive-compulsive disorder: A voxel-based morphometry study. *Psychiatry Research - Neuroimaging*, 184(1), 29-37.
- Van Den Heuvel, O. A., Remijnse, P. L., Mataix-Cols, D., Vrenken, H., Groenewegen, H. J., Uylings, H. B. M., ..., Veltman, D. J. (2009). The major symptom dimensions of obsessive-compulsive disorder are mediated by partially distinct neural systems. *Brain*, 132(4), 853-868.
- van Velzen, L. S., Vriend, C., de Wit, S. J., & van den Heuvel, O. A. (2014). Response inhibition and interference control in obsessive-compulsive spectrum disorders. *Frontiers in Human Neuroscience*, 8, 419.
- van Westen, M., Rietveld, E., Figeo, M., & Denys, D. (2015). Clinical Outcome and Mechanisms of Deep Brain Stimulation for Obsessive-Compulsive Disorder. *Current Behavioral Neuroscience Reports*, 2(2), 41-48.
- Wager, T. D., Sylvester, C.-Y. C., Lacey, S. C., Nee, D. E., Franklin, M., & Jonides, J. (2005). Common and unique components of response inhibition revealed by fMRI. *NeuroImage*, 27(2), 323-340.
- Yoo, S. Y., Roh, M.-S., Choi, J.-S., Kang, D.-H., Ha, T. H., Lee, J.-M., ..., Kwon, J. S. (2008). Voxel-based morphometry study of gray matter abnormalities in obsessive-compulsive disorder. *Journal of Korean Medical Science*, 23(1), 24-30.