

**RESEARCH ARTICLE**

# Interpreting injury recidivism in a rural post-medieval male individual from Bucelas, Portugal

Nathalie Antunes-Ferreira<sup>1,2,3</sup>  | Carlos Prates<sup>4</sup> | Francisco Curate<sup>5,6,7</sup> 

<sup>1</sup>Centro de Investigação Interdisciplinar Egas Moniz, Instituto Universitário Egas Moniz, Monte da Caparica, Portugal

<sup>2</sup>Laboratório de Ciências Forenses e Psicológicas Egas Moniz, Egas Moniz Cooperativa de Ensino Superior, Monte da Caparica, Portugal

<sup>3</sup>Laboratory of Biological Anthropology and Human Osteology, CRIA/FCSH, Universidade Nova de Lisboa, Lisboa, Portugal

<sup>4</sup>Medical Clinic, IMI art, Imagens Médicas Integradas/Affidea, Lisboa, Portugal

<sup>5</sup>Research Centre for Anthropology and Health, Department of Life Sciences, University of Coimbra, Coimbra, Portugal

<sup>6</sup>Laboratory of Forensic Anthropology, Department of Life Sciences, University of Coimbra, Coimbra, Portugal

<sup>7</sup>School of Technology of Tomar, Polytechnic Institute of Tomar, Tomar/Mação, Portugal

**Correspondence**

Nathalie Antunes-Ferreira, Centro de Investigação Interdisciplinar Egas Moniz, Instituto Universitário Egas Moniz, Campus Universitário Quinta da Granja, Monte de Caparica, 2829-511 Caparica, Portugal.  
Email: [naferreira@egasmoniz.edu.pt](mailto:naferreira@egasmoniz.edu.pt)

**Abstract**

Injury recidivism studies assess the lived experience of individuals who endure multiple traumatic incidents, conveying a nuanced contextualization of individual suffering within a reticulate of social and cultural processes. During a recent archaeological excavation, a skeleton of a middle-aged male dating to the 17th–18th centuries AD was excavated in the churchyard of the Chapel of the Holy Spirit in Bucelas (Portugal). This individual exhibited a mixture of healed and healing fractures that prompted poor functional long-term outcomes and an increase in the risk of death. Macroscopic and medical imaging (computerized tomography) analyses revealed lesions in the right shoulder, right and left ribs, fifth right proximal phalanx and right distal femur. Fracture complications include myositis ossificans and chronic osteomyelitis. The results are interpreted in the broader sociocultural circumstances of Bucelas during the early modern period, in order to investigate the causes of this individual's accumulated trauma and the possibility of health-related care associated with it.

**KEYWORDS**

care, fractures, injury recidivism, myositis ossificans, osteomyelitis, palaeopathology, post-medieval

## 1 | INTRODUCTION

Skeletal trauma is a pervasive find in human remains from different archaeological contexts, with fractures being the most common type of trauma observed in historical assemblages (Ortner, 2003; Redfern & Roberts, 2019). The anatomical and sociocultural implications of trauma in the past are complex and multidimensional; as such, the theoretical landscapes, research questions and methodological systems used to investigate skeletal injuries are diverse (Gilmour, Brickley, Jurriaans, & Prowse, 2019; Lovell, 1997; Redfern & Roberts, 2019). Palaeopathological studies of skeletal injury have made important contributions to the interpretation of biocultural contexts in the past, addressing issues such as interpersonal violence (Erdal & Erdal, 2012; Fernández-Crespo, 2017; Pfeiffer, 2016; Piombino-Mascalì, Bedini, Curate, Lippi, & Mallegni, 2006), age and gender (Curate, Lopes, & Cunha, 2010; de la Cova, 2012; Ives, Mant, de la Cova, &

Brickley, 2017; Robbins, Gray, Mushrif-Tripathy, & Sankhyan, 2012), social inequality and structural violence (Antunes-Ferreira, 2015; de la Cova, 2017, 2012, 2010; Fernandes, Liberato, Marques, & Cunha, 2017; Osterholtz, 2012), subsistence strategies (Domett & Tayles, 2006; Lambert & Welker, 2017), territorial organisation (Collier & Primeau, 2019; Šlaus, Novak, Bedić, & Strinović, 2012), child abuse (Gaither, 2012; Wheeler, Williams, Beauchesne, & Dupras, 2013), surgical procedures or medical assistance (Binder et al., 2016; Giuffra & Fornaciari, 2017) and the provision of care (Dequeker et al., 1997; Lovell, 2016).

After decades of population-focused approaches—valuing above all models that addressed wider evolutionary and epidemiological questions—research agendas in palaeopathology became again more heterogeneous, with an ongoing rehabilitation of richly contextualised, theory-governed, studies of individuals (Grauer & Buikstra, 2019). Case studies, which focus on certain skeletal lesions

or diagnostic topics, and osteobiographies, emphasize a plethora of individualising features, systematically intertwined in the biological, social, cultural and political aspects of an individual's life (Grauer & Buikstra, 2019; Robb, 2002; Stodder & Palkovich, 2012), being paramount in the current redefinition of the palaeopathological ethos. As noted by Paul Farmer (2003), the experience of suffering is not suitably revealed by statistics, and to explain it one should embed individual biographies within their cultural, social, political or economic contexts. More nuanced theoretical frameworks for the study of individual experiences of health and disease comprise the bioarchaeology of care, life course perspectives and the bioarchaeology of personhood (including fictive narratives) (Boutin, 2016; Glencross, 2011; Tilley, 2015b; Watkins & Muller, 2015).

In this work, we evaluated the functional and social consequences of several skeletal injuries suffered by a male individual from the Chapel of the Holy Spirit in Bucelas (Lisbon, Portugal). The interpretative challenges posed by the combination of different types of trauma and its likely functional impacts—at the individual and societal levels—were addressed through the perspectives of injury recidivism as defined in bioarchaeology (Judd, 2002, 2017; Mant, 2019) and the bioarchaeology of care (Tilley, 2015b; Tilley & Oxenham, 2011; Tilley & Schrenk, 2017).

## 2 | MATERIALS AND METHODS

The Chapel of the Holy Spirit (Figure 1) was located in the rural village of Bucelas, in the environs of Lisbon (Portugal). It was built during the 14th century and destroyed in the early 20th century AD (Fernandes, 2013). The associated churchyard was probably used between the 15th and the 19th centuries. During a recent archaeological excavation, 157 primary inhumations comprising 98 adults (59 males, 33 females and six of unknown sex) and 59 nonadults, were exhumed (Table 1). Individuals were shrouded and placed directly in the grave soil, in supine position with the head facing west and the

feet facing east. The prevalence of fractures in the overall adult sample is 18.4% (18/98).

The focus of this study is the skeleton of individual #15, which stands out from the remaining sample as it shows evidence of multiple injuries with major sequelae. This inhumation is probably from the 17th–18th centuries, as suggested by archaeological data, including the presence of blue-on-white Portuguese faience that was produced during this chronological period (Casimiro & Sequeira, 2017; Estêvão & Antunes-Ferreira, 2020). The skeleton was complete and well preserved (Figure 2). Sex was estimated from the morphological features of the skull and pelvis (Bruzek, 2002; Buikstra & Ubelaker, 1994), indicating a male individual. Age-at-death assessment suggests the individual was older than 40 years of age: the analysis of the sternal end of the fourth rib points to an age interval of 43–55 years old (İşcan, Loth, & Wright, 1984), the pubic symphysis to an age interval of 23–57 years old (Brooks & Suchey, 1990) and the auricular surface metamorphosis to an age above 50 years old (Lovejoy, Meindl, Pryzbeck, & Mensforth, 1985). The physiological length of the left femur (428 mm) indicates an approximate stature of 161 cm (Mendonça, 2000).

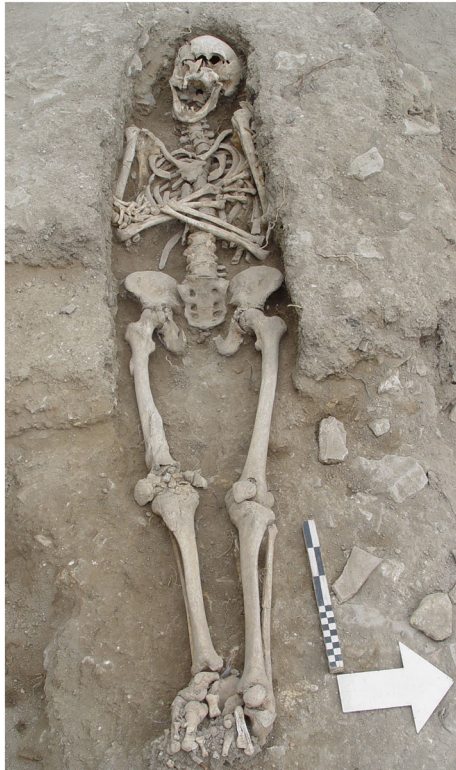Computerized tomography (CT) scan analysis of the right femur (80 kV, 250 mA, slices 0.6/0.3 mm, 1315 images) and the right scapula (80 kV, 250 mA, slices 0.6/0.3 mm, 537 images) was performed with a Siemens Somatom Definition AS 128. Digital radiography analysis of the right femur (60 kV, 56.0 mA) and the left second metacarpal (60 kV, 20.0 mA) was implemented with Siemens Iconos R200 equipment and Kodak DirectView CR850 film. The cortical index (MCI) at the second metacarpal midpoint was estimated according to Ives and Brickley (2004) and the Z-Score (describes a value's association with the mean of a group of values, being measured in terms of standard deviations from the mean) was calculated comparing the obtained value with the sample means for late 19th to early 20th centuries older males provided by Curate et al. (2019). The palaeopathological analysis followed the recommendations detailed in standard textbooks (Buikstra, 2019; Buikstra & Ubelaker, 1994; Ortner, 2003).



**FIGURE 1** The Chapel of the Holy Spirit that was destroyed in the early 20th century (source: Anselmo Braamcamp Freire's Documentation Center of the Municipal Museum of Loures)

**TABLE 1** Sex and age-at-death distribution of the individuals from the Chapel of the Holy Spirit (adult age categories adapted from Buikstra & Ubelaker, 1994)

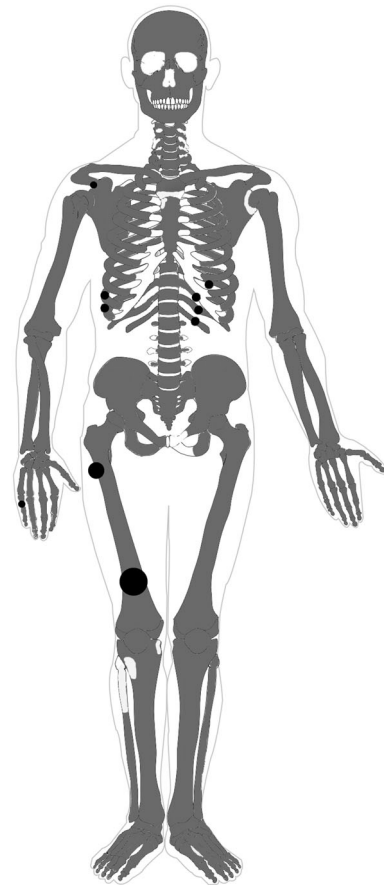
| Age categories       | Females | Males | Unknown sex | Total |
|----------------------|---------|-------|-------------|-------|
| Nonadults            | —       | —     | 59          | 59    |
| Young adults         | 4       | 14    | 1           | 19    |
| Middle adults        | 17      | 29    | 1           | 47    |
| Old adults           | 8       | 7     | 0           | 15    |
| Indeterminate adults | 4       | 9     | 4           | 17    |



**FIGURE 2** Skeleton of the male individual #15 in situ

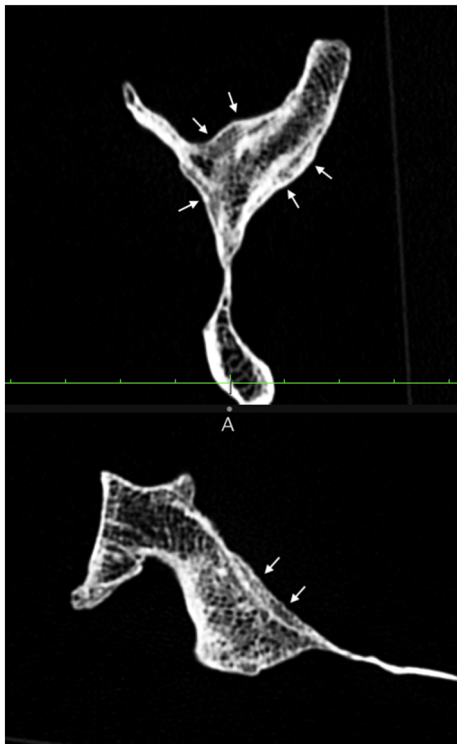
### 3 | RESULTS

The male individual under study had evidence of multiple trauma (Figure 3). Macroscopic analysis revealed the presence of new bone formation in the right acromial process, whereas CT data analysis exposed three distinct areas of superficial layers of bone deposition overlaying the normal cortical bone, at partial insertion areas of the main rotator cuff muscles (Figure 4). The new bone was more evident on the bed of the *supraspinatus* muscle, but it is also observed at the insertion of the *infraspinatus* and *subscapularis* muscles. Both the right acromion and proximal humerus (in the articular surface and in the greater tubercle) display evidence of eburnation. Fractures were identified in six ribs (ninth and 10th right, and ninth, 10th, 11th and 12th left) by the presence of a callus located in the middle (left ribs) to the sternal (right ribs) portion of the shaft (Figure 5). Fractures were well-healed, except for an ununited fracture in the 11th left rib (this rib also



**FIGURE 3** Injuries and fractures distribution in the skeleton. The grey colour represents the bones present. The dark circles indicate the injured bones

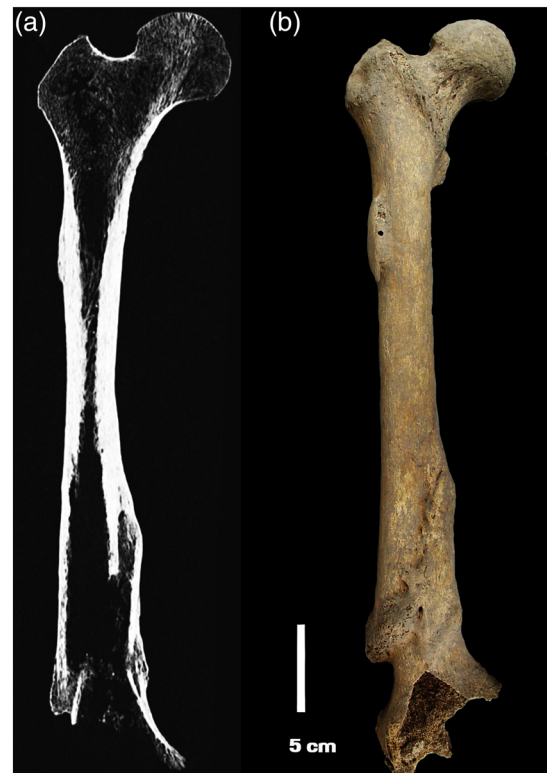exhibited a well-remodelled fracture, located ~20 mm to the sternal side). The unfused rib fracture presented with woven bone, showing active remodelling (Figure 6). Right fifth proximal hand phalanx presents extensive new bone formation with thickness and deformation in the dorsal middle diaphysis. The right femur displays two striking traumatic lesions: A bone growth consistent with traumatic myositis ossificans (MO) is noticeable on the lateral proximal diaphysis, and its distal diaphysis exhibits an extra-articular, supracondylar, displaced comminuted fracture accompanied by deformity and shortening of the diaphysis (Figure 7 and Table 2). An extensive callus and MO were identified around the injured area. The CT axial images additionally show radiographic signs of chronic osteomyelitis, revealing abundant sclerotic bone near the fractured cortex, along both the endosteal and periosteal surfaces. In at least three levels, there are clear evidence of three cloacae (Figure 8). A thinner, more irregular, and less dense arch of the intramedullary displaced cortex represents a partial sequestrum. Secondary alterations include the shortening of the femur (maximum length difference of 22 mm between sides, resulting in dysmetria of the inferior limbs), and severe osteoarthritis of the right knee. The MCI was 41.1 (Z-Scores between  $-0.885$  [age class 50–59 years old] and  $-0.450$  [age class 80 + years old]), probably lower for age.



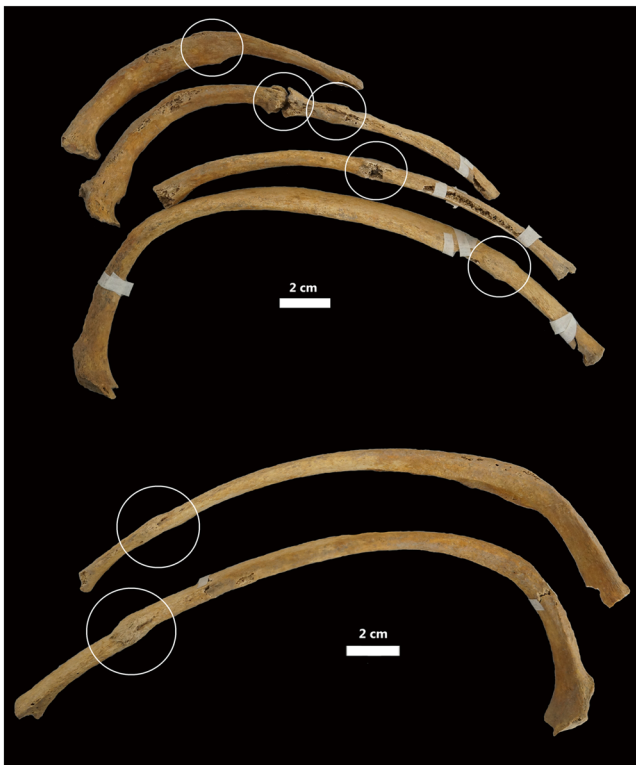
**FIGURE 4** Computerized tomography (CT) multiplanar reconstruction of oblique views (sagittal and axial) of the right scapula (arrows showing areas of new bone deposition)



**FIGURE 6** Inferior view of the 11th left rib with two fractures. The unfused fracture shows woven bone, indicating active remodelling



**FIGURE 7** Distal fracture of the right femur, with bone impaction and myositis ossificans in the proximal region: (a) CT multiplanar reconstruction coronal view of the right femur; (b) macroscopical anterior view of the right femur



**FIGURE 5** Fractures in the left (above) and right (below) ribs (superior view). Notice the different locations of the fractures in the shaft and stages of remodelling

#### 4 | DISCUSSION

The male individual from Bucelas shows evidence of multiple injuries, with a combination of healed and healing trauma, and although some of the observed fractures could have resulted from a single event—particularly those that were well-healed—other injuries were certainly experienced in separate incidents. The 11th left rib showed two fractures in different locations, one well-remodelled and other still healing. Other ribs exhibited well-healed fractures. A severe fracture of the distal right femur showed extensive remodelling, whereas injuries in a right

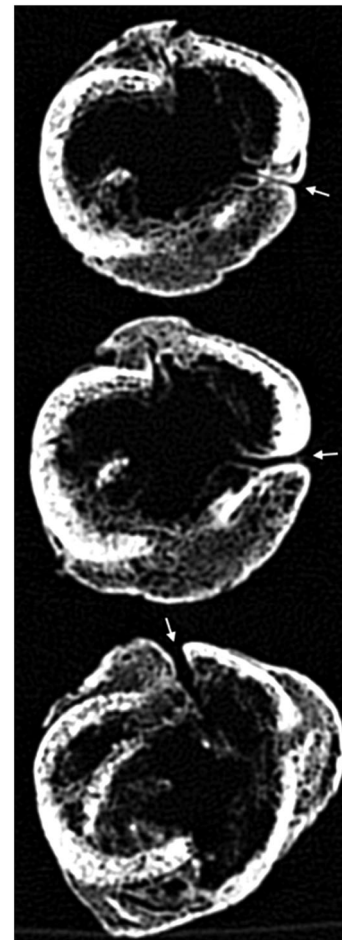


**TABLE 2** Description of the fracture of the right distal femur after the *Fracture Recording Method* depicted in Redfern and Roberts (2019)

|                                      |  |
|--------------------------------------|--|
| Sex and age                          | Male, +40 years old  |
| Bone and affected segment            | Right distal femur   |
| Fracture position                    | Distal, supracondylar  |
| Type                                 | Comminuted fracture (with at least three discontinued fragments of cortical bone)  |
| State of healing                     | Healed fracture, extensive callus of lamellar bone   |
| Infection                            | Osteomyelitis: three cloacae and a partial sequestrum  |
| Underlying pathology                 | No   |
| Joint degeneration                   | Osteoarthritis (eburnation) in all bones of the right knee   |
| Angulation of the fractured segments | Good (<45°): slight (9°) coronal counterclockwise angulation of the lower medial diaphyseal fragment. In the sagittal plane the lowest fragment reaches 20° of anterior deviation                      |
| Linear/rotational deformity          | Present rotational deformity: 23° of measured retroversion of the femoral neck versus the lower femur segment, showing an abnormal counterclockwise rotation of the lower supracondylar fragment       |
| Amount of overlap/apposition         | Five to six cm of cortical diaphyseal fragments overlap at the medial lower third of the femur. Due to the multiple fragments (at least three) the contact between fracture segments is not achievable |
| Alignment of the bone                | Moderate misalignment: mediolateral and longitudinal displacement of the broken segments   |

proximal hand phalanx and right acromial process were also well-remodelled. Also, the few existing epidemiological studies suggest that in a traumatic event that produces multiple fractures, certain skeletal regions tend to be more affected concurrently, for example, fractures of the shoulder girdle are commonly associated with thoracic fractures, including spinal fractures; and finger fractures are associated with fractures of the metacarpals and the distal forearm (Feichtinger et al., 2019). The fractures that affected this individual do not correspond to any of the commonly observed multifracture patterns.

As such, the categorisation of this individual as an *injury recidivist* is plausible (Mant, 2019). The use of the term is sometimes equivocal, with different operational definitions in clinical and bioarchaeological research (Judd, 2017; Redfern, Judd, & DeWitte, 2017), but it is a powerful concept that offers a nuanced understanding of the intricate relationships between trauma, individual experiences and social contexts (de la Cova, 2017; Grauer & Buikstra, 2019; Redfern et al., 2017). This case also highlights the excellent resolution and 3D multiplanar diagnostic capacities of CT when compared with the 2D data of traditional radiography.



**FIGURE 8** Computerized tomography (CT) multiplanar reconstruction of axial views (three levels) of the lower diaphysis of the right femur (arrows showing three distinct cloacae)

The lesions in the shoulder girdle area, particularly those in the right acromial process, were probably produced by an exogenous cause, such as trauma or infection. In both cases, inflammation, a vascular response to traumatic or infectious tissue damage, acted as a stimulus to a healing and repair process that may include an osteoblastic reaction, leading to new bone apposition at partial insertion regions of the main three rotator cuff muscles. These findings suggest a musculotendinous trauma of the shoulder as the very probable cause. Shoulder injuries are common in both young and ageing population, and shoulder pain is a frequent associated problem, responsible for lengthy periods of disability, loss of productivity, work absenteeism and inability to accomplish domestic activities (Linsell et al., 2006).

Rib fractures are common and often result from accidents, falls or direct blows to the chest (Brickley, 2006; Galloway & Wedel, 2014). Fractures in the ribs were in different stages of recovery, with at least one fracture on the left side still in the process of healing. Complications related to rib fracture include pain, hemothorax, pneumothorax, and pulmonary contusion. Fractures of the ninth, 10th and 11th ribs, commonly caused by rotational types of injury, are associated with intra-abdominal injury, particularly liver (right ribs) and spleen (left ribs) injuries (Galloway & Wedel, 2014; Talbot et al., 2017). In fact,

lower rib injury has long been regarded as a marker for internal organ damage (Talbot et al., 2017).

Fractures of the phalanges—and particularly those in the proximal phalanx of the fifth digit—are among the most common of the upper extremity. Their incidence is greater in males, with a peak between 10 and 40 years old, and can be produced by road traffic accidents, falling objects, assault, falls and even trivial activities, such as jar opening (Singh, Jain, & Mruthyunjaya, 2011). Phalangeal fractures are also relatively common in archaeological contexts, and fractures of the hand are frequently associated with other injuries (Kilgore, Jurmain, & Van Gerven, 1997; Mant, 2019; Redfern, 2010).

Fractures of the distal femur are very infrequent and severe, associated with high morbidity and mortality, and occur normally either as high-energy trauma in younger men or low-energy injuries in older women with osteoporosis (Streubel, Ricci, Wong, & Gardner, 2011). The recorded fracture is extra-articular and consistent with an open wound. The femoral fracture is consistent with high-impact trauma (Villa et al., 2013), displaying bone impaction, secondary inferior member dysmetria and osteoarthritis (OA) of the knee, development of exogenous osteomyelitis and MO. Its combination with other traumatic lesions—although it is improbable that all fractures occurred in the same event—also suggests a high-impact traumatic hazard.

Lesions in the femoral diaphysis include two occurrences of MO, probably posttraumatic. MO is a syndrome characterized by a non-neoplastic heterotopic ossification (i.e., calcification) in an area that has been exposed to trauma. Symptoms include pain, local tenderness and stiffness, and functional compromise of the affected leg (Buselli et al., 2010). Also, the presence of cloacae and *sequestrum* are suggestive of exogenous posttraumatic osteomyelitis. Posttraumatic osteomyelitis is a common complication of open fractures, and it is frequently caused by *Staphylococcus aureus* (polymicrobial infections are also common) (Sheehy et al., 2010). Individuals with chronic osteomyelitis endure pain and disability, and persistent discharges of putrid pus. Long-term failure of medical management can cause mobility deficits, prolonged support, depression, unemployment, and death (Huang et al., 2016). Infected fractures and osteomyelitis in adults have been infrequently described in the palaeopathological literature (Flensburg, Suby, & Martínez, 2013; Judd & Roberts, 1999; Ortner, 2003; Wood-Jones, 1910), a likely reflection of both the low prevalence of open fractures and associated high mortality (Redfern & Roberts, 2019).

The aforesaid multifracture scenario undoubtedly prompted poor functional long-term outcomes for this individual, with a prolonged period of recovery, with probable immobilisation and bed rest, and an increase in the risk of death. OA observed in the knee suggests that the limb was used after the fracture, and locomotion after fracture could have been aided by some type of crutch—but it was not found any evidence of its usage. Some occupational activities could have been performed by this individual, including basketry, but most agricultural works would have been unfeasible.

Cortical bone mass measured at the second metacarpal was possibly low for age, as suggested by the documented Z-Scores, and, although some fractures (i.e., osteoporotic fractures; Curate, 2014) are linked to low bone mass, the recorded osteopenia most likely

stemmed from decreased mechanical loading: there is a possibility that bone loss occurred after fracture and not before (Brickley & Ives, 2008). In fact, fractures and other injuries often compromise the functional capability of individuals, affecting their independence in walking, obtaining food, and maintaining personal hygiene. In the case of a significant impact on individual functional capacity, the provision of care (healthcare or other) by third parties is essential for survival (Tilley, 2015a; Tilley & Oxenham, 2011).

Documentary sources refer to the existence of the Hospital of the Holy Spirit in Bucelas, as well as the Confraternity of the Holy Spirit, in its environs during this chronological period, which gave material and health support to the pilgrims, poor, sick and dying people (Fernandes, 2013; Villaverde, 2018)—but community support networks most probably involved relatives, and possibly town physicians or even barber-surgeons (António & Curate, 2019). The Hospital of the Holy Spirit provided food, rest, and minor treatments to its patients (Fernandes, 2013; Villaverde, 2018). Family care towards the frail, the elder or the infirm is still a normative behaviour of great social and cultural relevance in contemporary societies (Toseland, Smith, & McCallion, 2001). In the southern European Catholic societies, arranged around heterogeneous family structures (between the nuclear, stem and/or extended families), solidarity and care towards the vulnerable was typically the responsibility of the families, and within these, of female family members (Leandro, 2006; Reher, 1998).

The aetiology of the observed injuries is probably multifactorial, reflecting a combination of individual agency and socially defined circumstances. For example, middle-aged men generally experience multiple injuries more frequently than women (Redfern et al., 2017). Additionally, historical records suggest that most of the inhabitants of Bucelas during the early modern period were rural workers, with some references to skilled craft workers, particularly coopers, basket makers, bricklayers, blacksmiths and fur beaters (Villaverde, 2018). It is therefore conceivable that some, if not all, of the described injuries resulted from work-related accidents. Bucelas is an ancient wine-region, since at least the Roman colonisation of the Iberian Peninsula. After the Peninsular War (1807–1814), Lisbon «Hock» (white wine) became an important export to England (Robinson, 2006). Farming has always been among the most hazardous occupations (Judd & Roberts, 1999). Occupational health risks of winery labourers comprise both specific hazards, such as exposure to carbon dioxide in confined spaces, and the same injuries faced by agriculture workers in general, including skeletal injuries caused by falls or farm accidents (Anaya-Aguilar, Suárez-Cebador, Rubio-Romero, & Galindo-Reyes, 2018). Moreover, the severity of recorded lesions prompted an extended period of recovery, with probable social sequelae, such as unemployment and impoverishment.

Substance abuse has been consistently linked with injury recidivism, both in rural and urban populations. Alcohol consumption, in particular, is associated with a higher risk of trauma and injury recidivism in modern populations (Cordovilla-Guardia, Vilar-López, Lardelli-Claret, & Fernández-Mondéjar, 2017; Nunn, Erdogan, & Green, 2016; Toschlog et al., 2007). It is not possible to reconstruct this individual's experience with substance abuse, but in the larger social context of 17<sup>th</sup> – 18<sup>th</sup>

centuries Bucelas it is plausible to connect injury recidivism with prevalent alcohol consumption and abuse. In Portugal, during the 18th century, the consumption of alcohol (especially wine and brandy) increased, with a growing perception of alcoholism as a social problem. Government policies, church homilies and newspaper headlines tried to oppose a thriving *collective disease*, then accountable for impoverishment, interpersonal and domestic violence, crime, suicide, incest, prostitution and all sorts of physical injuries (Silva, 2007; Vaquinhas, 1995). The association of injury recidivism and alcoholism is further diffracted by poverty (the location of this individual's grave, outside the religious building, and the modesty of the burial, point to an underprivileged socio-economic background), producing a *pathogenic social spiral* in the larger landscape of structural violence (Herrick & Reubi, 2017).

The type, severity and pattern of injuries observed delimit and clarify to a point the corporeal experiences of this male within the biological and social processes of Bucelas. The latter are especially meaningful to integrate individual accumulated trauma in the social fabric, contextualising different but integrated loci of community life, such as work and related accidents, societal relief, addictive behaviour, interpersonal and structural violence.

## 5 | FINAL REMARKS

Injury recidivism is a major subject of research in palaeopathology and bioarchaeology, and the study of trauma circumstances in which a combination of antemortem healed, healing, or perimortem elements is present conveys a compelling assessment of the lived experiences of individuals that suffer multiple traumatic incidents (Mant, 2019; Redfern et al., 2017). A male individual from Bucelas accumulated multiple injuries in at least two incidents. The observed skeletal trauma—including injuries in the right shoulder, several ribs, right hand 5th proximal phalanx and right distal femur, with traumatic MO and osteomyelitis—undeniably prompted a long-term functional incapacity, probably framed by charity or family support but also by work-related accidents, dependency behaviour and structural violence, and an increased risk of death.

## ACKNOWLEDGEMENTS

Thanks are due to the Clinic *Imagens Médicas Integradas/Affidea* (Lisbon, Portugal), to the Department of Culture of the Loures township and to the archaeologist Florbela Estêvão.

## DATA AVAILABILITY STATEMENT

The data that support the findings of this study are available from the corresponding author, (N. A. F.), upon reasonable request.

## CONFLICT OF INTERESTS

The authors declare no conflict of interest.

## ORCID

Nathalie Antunes-Ferreira  <https://orcid.org/0000-0002-0146-6369>

Francisco Curate  <https://orcid.org/0000-0002-0480-209X>

## REFERENCES

- Anaya-Aguilar, R., Suárez-Cebador, M., Rubio-Romero, J. C., & Galindo-Reyes, F. (2018). Delphi assessment of occupational hazards in the wineries of Andalusia, in southern Spain. *Journal of Cleaner Production*, 196, 297–303. <https://doi.org/10.1016/j.jclepro.2018.06.008>
- António, T., & Curate, F. (2019). “De Doenças Esporádicas Farei Algumas Histórias”: Gaspar Lopes Henriques de Chaves (1729–1796), médico do Partido da Vila de Almada. *Al-Madan*, 22, 153–158.
- Antunes-Ferreira, N. (2015). Antropologia funerária e paleobiologia das populações pós-medievais portuguesas: Os casos de Nossa Senhora da Anunciada e Espírito Santo, University of Lisboa.
- Binder, M., Eitler, J., Deutschmann, J., Ladstätter, S., Glaser, F., & Fiedler, D. (2016). Prosthetics in antiquity—An early medieval wearer of a foot prosthesis (6th century AD) from Hemmaberg/Austria. *International Journal of Paleopathology*, 12, 29–40. <https://doi.org/10.1016/j.ijpp.2015.11.003>
- Boutin, A. T. (2016). Exploring the social construction of disability: An application of the bioarchaeology of personhood model to a pathological skeleton from ancient Bahrain. *International Journal of Paleopathology*, 12, 17–28. <https://doi.org/10.1016/j.ijpp.2015.10.005>
- Brickley, M. B. (2006). Rib fractures in the archaeological record: A useful source of sociocultural information? *International Journal of Osteoarchaeology*, 16, 61–75. <https://doi.org/10.1002/oa.809>
- Brickley, M. B., & Ives, R. (2008). *The bioarchaeology of metabolic bone disease*. Oxford: Academic Press. <https://doi.org/10.1016/B978-0-12-370486-3.00002-0>
- Brooks, S., & Suchey, J. M. (1990). Skeletal age determination based on the os pubis. *Human Evolution*, 5, 227–238. <https://doi.org/10.1007/BF02437238>
- Bruzek, J. (2002). A method for visual determination of sex, using the human hip bone. *American Journal of Physical Anthropology*, 168, 157–168. <https://doi.org/10.1002/ajpa.10012>
- Buikstra, J. E. (2019). In J. E. Buikstra (Ed.), *Ortner's identification of pathological conditions in human skeletal remains*. London: Academic Press.
- Buikstra, J. E., & Ubelaker, D. (1994). *Standards for data collection from human skeletal remains*. Arkansas: Arkansas Archaeological Survey.
- Buselli, P., Cocoli, V., Notarnicola, A., Messina, S., Saggini, R., Tafuri, S., ... Moretti, B. (2010). Shock waves in the treatment of Post-Traumatic Myositis Ossificans. *Ultrasound in Medicine and Biology*, 36, 397–409. <https://doi.org/10.1016/j.ultrasmedbio.2009.11.007>
- Casimiro, T., & Sequeira, J. (2017). Faiança portuguesa dos séculos XVI–XVIII recuperada no Tejo. *Cira-Arqueologia*, 5, 260–274.
- Collier, L., & Primeau, C. (2019). A tale of two cities: A comparison of urban and rural trauma in Medieval Denmark. *International Journal of Paleopathology*, 24, 175–184. <https://doi.org/10.1016/j.ijpp.2018.10.002>
- Cordovilla-Guardia, S., Vilar-López, R., Lardelli-Claret, P., & Fernández-Mondéjar, E. (2017). Alcohol or drug use and trauma recidivism. *Nursing Research*, 66, 399–404. <https://doi.org/10.1097/NNR.0000000000000231>
- Curate, F. (2014). Osteoporosis and paleopathology: A review. *Journal of Anthropological Sciences*, 92, 119–146. <https://doi.org/10.4436/JASS.92003>
- Curate, F., Lopes, C., & Cunha, E. (2010). A 14th–17th century osteoporotic hip fracture from the Santa Clara-a-Velha Convent in Coimbra (Portugal). *International Journal of Osteoarchaeology*, 20, 591–596. <https://doi.org/10.1002/oa.1076>
- Curate, F., Perinha, A., Silva, A. M., Cunha, E., Umbelino, C., & Nogueira, C. (2019). Metacarpal cortical bone loss and osteoporotic fractures in the Coimbra Identified Skeletal Collection. *International Journal of Osteoarchaeology*, 29, 73–81. <https://doi.org/10.1002/oa.2717>
- de la Cova, C. (2010). Cultural patterns of trauma among 19th-century-born males in cadaver collections. *American Anthropologist*, 112, 589–606. <https://doi.org/10.1111/j.1548-1433.2010.01278.x>

- de la Cova, C. (2012). Patterns of trauma and violence in 19th-century-born African American and Euro-American females. *International Journal of Paleopathology*, 2, 61–68. <https://doi.org/10.1016/j.ijpp.2012.09.009>
- de la Cova, C. (2017). Fractured lives: Structural violence, trauma, and recidivism in urban and institutionalized 19th-century-born African Americans and Euro-Americans. In C. E. Tegtmeier, & D. L. Martin (Eds.), *Broken bones, broken bodies: Bioarchaeological and forensic approaches for accumulative trauma and violence* (pp. 153–180). Lanham: Lexington Books.
- Dequeker, J., Ortner, D. J., Stix, A. I., Cheng, X. G., Brys, P., & Boonen, S. (1997). Hip fracture and osteoporosis in a XIth Dynasty female skeleton from Lisht, upper Egypt. *Journal of Bone and Mineral Research: the Official Journal of the American Society for Bone and Mineral Research*, 12, 881–888. <https://doi.org/10.1359/jbmr.1997.12.6.881>
- Domett, K. M., & Tayles, N. (2006). Adult fracture patterns in prehistoric Thailand: A biocultural interpretation. *International Journal of Osteoarchaeology*, 16, 185–199. <https://doi.org/10.1002/oa.815>
- Erdal, Y. S., & Erdal, O. D. (2012). Organized violence in Anatolia: A retrospective research on the injuries from the Neolithic to Early Bronze Age. *International Journal of Paleopathology*, 2, 78–92. <https://doi.org/10.1016/j.ijpp.2012.09.014>
- Estêvão, F., & Antunes-Ferreira, N. (2020). *Relatório da Intervenção Arqueológica na Rua Marquês de Pombal, em Bucelas (Loures)*. Loures: Câmara Municipal de Loures. [unpublished report]
- Farmer, P. (2003). *Pathologies of power: Health, human rights and the new war on the poor*. Berkeley: University of California Press. <https://doi.org/10.1017/CBO9781107415324.004>
- Feichtinger, X., Kocijan, R., Mittermayr, R., Baierl, A., Schanda, J., Wakolbinger, R., ... Muschitz, C. (2019). Fracture patterns in patients with multiple fractures: the probability of multiple fractures and the most frequently associated regions. *European Journal of Trauma and Emergency Surgery*, 46, 1151–1158. <https://doi.org/10.1007/s00068-019-01087-4>
- Fernandes, C. V. (2013). O (des)conhecido retábulo da antiga capela do Espírito Santo de Bucelas. *Arqueologia & História*, 62–63, 195–227.
- Fernandes, T., Liberato, M., Marques, C., & Cunha, E. (2017). Three cases of feet and hand amputation from Medieval Estremoz, Portugal. *International Journal of Paleopathology*, 18, 63–68. <https://doi.org/10.1016/j.ijpp.2017.05.007>
- Fernández-Crespo, T. (2017). New evidence of early chalcolithic interpersonal violence in the Middle Ebro Valley (Spain): Two Arrowhead injuries from the Swallet of Las Yurdinas II. *International Journal of Osteoarchaeology*, 27, 76–85. <https://doi.org/10.1002/oa.2445>
- Flensburg, G., Suby, J. A., & Martínez, G. (2013). A case of adult osteomyelitis in a Final Late Holocene hunter-gatherer population, Eastern Pampa. *International Journal of Paleopathology*, 3, 128–133. <https://doi.org/10.1016/j.ijpp.2013.05.002>
- Gaither, C. (2012). Cultural conflict and the impact on non-adults at Puruchuco-Huaquerones in Peru: The case for refinement of the methods used to analyze violence against children in the archeological record. *International Journal of Paleopathology*, 2, 69–77. <https://doi.org/10.1016/j.ijpp.2012.09.010>
- Galloway, A., & Wedel, V. (2014). Common circumstances of blunt force trauma. In V. Wedel, & A. Galloway (Eds.), *Broken bones: Anthropological analysis of blunt force trauma* (pp. 91–130). Springfield IL: Charles C Thomas.
- Gilmour, R. J., Brickley, M. B., Jurriaans, E., & Prowse, T. L. (2019). Maintaining mobility after fracture: A biomechanical analysis of fracture consequences at the Roman Sites of Ancaster (UK) and Vagnari (Italy). *International Journal of Paleopathology*, 24, 119–129. <https://doi.org/10.1016/j.ijpp.2018.09.002>
- Giuffra, V., & Fornaciari, G. (2017). Trepanation in Italy: A review. *International Journal of Osteoarchaeology*, 27, 745–767. <https://doi.org/10.1002/oa.2591>
- Glencross, B. A. (2011). Skeletal injury across the life course: Towards understanding social agency. In S. Agarwal, & B. A. Glencross (Eds.), *Social bioarchaeology* (pp. 390–409). Chichester: Blackwell Publishing Ltd. <https://doi.org/10.1002/9781444390537.ch14>
- Grauer, A. L., & Buikstra, J. E. (2019). Themes in paleopathology. In J. E. Buikstra (Ed.), *Ortner's identification of pathological conditions in human skeletal remains* (pp. 21–33). London: Academic Press. <https://doi.org/10.1016/B978-0-12-809738-0.00003-X>
- Herrick, C., & Reubi, D. (2017). Introduction. In C. Herrick, & D. Reubi (Eds.), *Global health and geographical imaginaries* (pp. iv–xxviii). New York: Routledge.
- Huang, C. C., Tsai, K. T., Weng, S. F., Lin, H. J., Huang, H. S., Wang, J. J., ... Hsu, C. C. (2016). Chronic osteomyelitis increases long-term mortality risk in the elderly: A nationwide population-based cohort study. *BMC Geriatrics*, 16, 1–7. <https://doi.org/10.1186/s12877-016-0248-8>
- İşcan, M. Y., Loth, S. R., & Wright, R. K. (1984). Metamorphosis at the sternal rib end: A new method to estimate age at death in white males. *American Journal of Physical Anthropology*, 65, 147–156. <https://doi.org/10.1002/ajpa.1330650206>
- Ives, R., & Brickley, M. B. (2004). A procedural guide to metacarpal radiogrammetry in archaeology. *International Journal of Osteoarchaeology*, 14, 7–17. <https://doi.org/10.1002/oa.709>
- Ives, R., Mant, M., de la Cova, C., & Brickley, M. (2017). A large-scale palaeopathological study of hip fractures from post-medieval urban England. *International Journal of Osteoarchaeology*, 27, 261–275. <https://doi.org/10.1002/oa.2536>
- Judd, M. (2002). Ancient injury recidivism: An example from the Kerma Period of Ancient Nubia. *International Journal of Osteoarchaeology*, 12, 89–106. <https://doi.org/10.1002/oa.587>
- Judd, M. (2017). Injury recidivism revisited: Clinical research, limitations, and implications for bioarchaeology. In C. E. Tegtmeier, & D. L. Martin (Eds.), *Broken bones, broken bodies—Bioarchaeological and forensic approaches for accumulative trauma and violence*. Lanham: Lexington Books.
- Judd, M., & Roberts, C. A. (1999). Fracture trauma in a Medieval British Farming Village. *American Journal of Physical Anthropology*, 109, 229–243. [https://doi.org/10.1002/\(SICI\)1096-8644\(199906\)109:2<229::AID-AJPA7>3.0.CO;2-Y](https://doi.org/10.1002/(SICI)1096-8644(199906)109:2<229::AID-AJPA7>3.0.CO;2-Y)
- Kilgore, L., Jurmain, R., & Van Gerven, D. (1997). Palaeoepidemiological patterns of trauma in a Medieval Nubian Skeletal Population. *International Journal of Osteoarchaeology*, 7, 103–114. [https://doi.org/10.1002/\(sici\)1099-1212\(199703\)7:2<103::aid-0a319>3.3.co;2-x](https://doi.org/10.1002/(sici)1099-1212(199703)7:2<103::aid-0a319>3.3.co;2-x)
- Lambert, P. M., & Welker, M. H. (2017). Traumatic injury risk and agricultural transitions: A view from the American Southeast and beyond. *American Journal of Physical Anthropology*, 162, 120–142. <https://doi.org/10.1002/ajpa.23103>
- Leandro, M. E. (2006). Transformações da família na história do Ocidente. *Theologica*, 41, 51–74.
- Linsell, L., Dawson, J., Zondervan, K., Rose, P., Randall, T., Fitzpatrick, R., & Carr, A. (2006). Prevalence and incidence of adults consulting for shoulder conditions in UK primary care; patterns of diagnosis and referral. *Rheumatology*, 45, 215–221. <https://doi.org/10.1093/rheumatology/kei139>
- Lovejoy, C. O., Meindl, R. S., Pryzbeck, T. R., & Mensforth, R. P. (1985). Chronological metamorphosis of the auricular surface of the ilium: A new method for the determination of adult skeletal age at death. *American Journal of Physical Anthropology*, 68, 15–28. <https://doi.org/10.1002/ajpa.1330680103>
- Lovell, N. C. (1997). Trauma analysis in paleopathology. *American Journal of Physical Anthropology*, 104, 139–170. [https://doi.org/10.1002/\(sici\)1096-8644\(1997\)104:139::aid-ajpa6>3.0.co;2-](https://doi.org/10.1002/(sici)1096-8644(1997)104:139::aid-ajpa6>3.0.co;2-)
- Lovell, N. C. (2016). Tiptoeing through the rest of his life: A functional adaptation to a leg shortened by femoral neck fracture. *International Journal of Paleopathology*, 13, 91–95. <https://doi.org/10.1016/j.ijpp.2016.03.001>



- Mant, M. (2019). Time after time: individuals with multiple fractures and injury recidivists in long eighteenth-century (c. 1666–1837) London. *International Journal of Paleopathology*, 24, 7–18. <https://doi.org/10.1016/j.ijpp.2018.08.003>
- Mendonça, M. C. (2000). Estimation of height from the length of long bones in a Portuguese adult population. *American Journal of Physical Anthropology*, 112, 39–48. [https://doi.org/10.1002/\(SICI\)1096-8644\(200005\)112:1<39::AID-AJPA5>3.0.CO;2-%23](https://doi.org/10.1002/(SICI)1096-8644(200005)112:1<39::AID-AJPA5>3.0.CO;2-%23)
- Nunn, J., Erdogan, M., & Green, R. S. (2016). The prevalence of alcohol-related trauma recidivism: A systematic review. *Injury*, 47, 551–558. <https://doi.org/10.1016/j.injury.2016.01.008>
- Ortner, D. J. (2003). *Identification of pathological conditions in human skeletal remains*. San Diego, CA: Academic Press. <https://doi.org/10.1016/B978-0-12-528628-2.X5037-6>
- Osterholtz, A. J. (2012). The social role of hobbling and torture: Violence in the prehistoric Southwest. *International Journal of Paleopathology*, 2, 148–155. <https://doi.org/10.1016/j.ijpp.2012.09.011>
- Pfeiffer, S. (2016). An exploration of interpersonal violence among Holocene foragers of Southern Africa. *International Journal of Paleopathology*, 13, 27–38. <https://doi.org/10.1016/j.ijpp.2016.01.001>
- Piombino-Mascalci, D., Bedini, E., Curate, F., Lippi, B., & Mallegni, F. (2006). Dois exemplos medievais de violência interpessoal na Itália setentrional. *Antropologia Portuguesa*, 22/23, 207–221.
- Redfern, R. (2010). A regional examination of surgery and fracture treatment in Iron Age and Roman Britain. *International Journal of Osteoarchaeology*, 20, 443–471. <https://doi.org/10.1002/oa.1067>
- Redfern, R. C., Judd, M. A., & DeWitte, S. N. (2017). Multiple injury and health in past societies: An analysis of concepts and approaches, and insights from a multi-period study. *International Journal of Osteoarchaeology*, 27, 418–429. <https://doi.org/10.1002/oa.2565>
- Redfern, R. C., & Roberts, C. A. (2019). Trauma. In J. E. Buikstra (Ed.), *Ortner's identification of pathological conditions in human skeletal remains* (pp. 211–284). London: Academic Press. <https://doi.org/10.1016/B978-0-12-809738-0.00009-0>
- Reher, D. S. (1998). Family ties in Western Europe: Persistent contrasts. *Population and Development Review*, 24, 203–234. <https://doi.org/10.2307/2807972>
- Robb, J. (2002). Time and biography: Osteobiography of the Italian Neolithic. In K. Hamilakis, M. Pluciennik, & S. Tarlow (Eds.), *Thinking through the body: Archaeologies of corporeality* (pp. 153–171). London: Kluwer Academic/Plenum. [https://doi.org/10.1007/978-1-4615-0693-5\\_9](https://doi.org/10.1007/978-1-4615-0693-5_9)
- Robbins, S. G., Gray, K., Mushrif-Tripathy, V., & Sankhyan, A. R. (2012). A peaceful realm? Trauma and social differentiation at Harappa. *International Journal of Paleopathology*, 2, 136–147. <https://doi.org/10.1016/j.ijpp.2012.09.012>
- Robinson, J. (2006). *The Oxford companion to wine*. Oxford: Oxford University Press.
- Sheehy, S. H., Atkins, B. A., Bejon, P., Byren, I., Wyllie, D., Athanasou, N. A., ... McNally, M. A. (2010). The microbiology of chronic osteomyelitis: Prevalence of resistance to common empirical anti-microbial regimens. *Journal of Infection*, 60, 338–343. <https://doi.org/10.1016/j.jinf.2010.03.006>
- Silva, S. S. (2007). Alcoolismo e Criminalidade no século XIX. O caso da ilha de S. Miguel (Açores). *Ler História*, 53, 93–111. <https://doi.org/10.4000/lerhistoria.2978>
- Singh, J., Jain, K., & Mruthyunjaya, R. R. (2011). Outcome of closed proximal phalangeal fractures of the hand. *Indian Journal of Orthopaedics*, 45, 432–438. <https://doi.org/10.4103/0019-5413.83764>
- Šlaus, M., Novak, M., Bedić, Ž., & Strinović, D. (2012). Bone fractures as indicators of intentional violence in the eastern adriatic from the antique to the late medieval period (2nd–16th century AD). *American Journal of Physical Anthropology*, 149, 26–38. <https://doi.org/10.1002/ajpa.22083>
- Stodder, A. L. W., & Palkovich, A. M. (2012). Osteobiography and bioarchaeology. In A. L. W. Stodder, & A. M. Palkovich (Eds.), *The Bioarchaeology of Individuals* (pp. 1–8). Gainesville: University Press of Florida. <https://doi.org/10.5744/florida/9780813038070.003.0001>
- Streubel, P. N., Ricci, W. M., Wong, A., & Gardner, M. J. (2011). Mortality after distal femur fractures in elderly patients. *Clinical Orthopaedics and Related Research*, 469, 1188–1196. <https://doi.org/10.1007/s11999-010-1530-2>
- Talbot, B. S., Gange, C. P., Chaturvedi, A., Klionsky, N., Hobbs, S. K., & Chaturvedi, A. (2017). Traumatic rib injury: Patterns, imaging pitfalls, complications, and treatment. *Radiographics*, 37, 628–651. <https://doi.org/10.1148/rg.2017160100>
- Tilley, L. (2015a). Accommodating difference in the prehistoric past: Revisiting the case of Romito 2 from a bioarchaeology of care perspective. *International Journal of Paleopathology*, 8, 64–74. <https://doi.org/10.1016/j.ijpp.2014.10.003>
- Tilley, L. (2015b). *Theory and practice in the bioarchaeology of care*. Heidelberg: Springer. <https://doi.org/10.1007/978-3-319-18860-7>
- Tilley, L., & Oxenham, M. F. (2011). Survival against the odds: Modeling the social implications of care provision to seriously disabled individuals. *International Journal of Paleopathology*, 1, 35–42. <https://doi.org/10.1016/j.ijpp.2011.02.003>
- Tilley, L., & Schrenk, A. A. (2017). *Introduction: New developments in the bioarchaeology of care*. DOI: [https://doi.org/10.1007/978-3-319-39901-0\\_1](https://doi.org/10.1007/978-3-319-39901-0_1)
- Toschlog, E. A., Sgraves, S. G., Bard, M. R., Schenarts, P. J., Goettler, C. C., Newell, M. A., & Rotondo, M. F. (2007). Rural trauma recidivism: A different disease. *Archives of Surgery*, 142, 77–81. <https://doi.org/10.1001/archsurg.142.1.77>
- Toseland, R. W., Smith, G. C., & McCallion, P. (2001). Family caregivers of the frail elderly. In A. Gitterman (Ed.), *Handbook of social work practice with vulnerable and resilient populations* (pp. 548–581). New York: Columbia University Press.
- Vaquinha, M. I. (1995). *Violência, justiça e Sociedade Rural. Os campos de Coimbra, Montemor-o-Velho e Penacova de 1858 a 1918*. Porto: Edições Afrontamento.
- Villa, P. E. A., Nunes, T. R., Gonçalves, F. P., Martins, J. S., de Lemos, G. S. P., & de Moraes, F. B. (2013). Avaliação clínica de pacientes com osteomielite crônica após fraturas expostas tratados no Hospital de Urgências de Goiânia, Goiás. *Revista Brasileira de Ortopedia*, 48, 22–28. <https://doi.org/10.1016/j.rbo.2012.03.004>
- Villaverde, M. (2018). Breves notas sobre a igreja de Bucelas e o seu contexto local. In C. V. Fernandes (Ed.), *Igreja Matriz de Loures* (pp. 11–19). Lisbon: Imprimatur.
- Watkins, R., & Muller, J. (2015). Repositioning the Cobb human archive: The merger of a skeletal collection and its texts. *American Journal of Human Biology*, 27, 41–50. <https://doi.org/10.1002/ajhb.22650>
- Wheeler, S., Williams, L., Beauchesne, P., & Dupras, T. L. (2013). Shattered lives and broken childhoods: Evidence of physical child abuse in ancient Egypt. *International Journal of Paleopathology*, 3, 71–82. <https://doi.org/10.1016/j.ijpp.2013.03.009>
- Wood-Jones, F. (1910). Fractured bones and dislocations. In G. E. Smith, & F. Wood-Jones (Eds.), *The archaeological survey of Nubia. Report for 1907–1908. Volume 2: report on the human remains* (pp. 293–342). Cairo: National Printing Department.

**How to cite this article:** Antunes-Ferreira N, Prates C, Curate F. Interpreting injury recidivism in a rural post-medieval male individual from Bucelas, Portugal. *Int J Osteoarchaeol*. 2020;1–9. <https://doi.org/10.1002/oa.2943>