Diseases of the Esophagus (2008) **21**, 1–8
DOI: 10.1111/j.1442-2050.2007.00795.x

DISEASES OF THE ESOPHAGUS

Review article

Zenker's diverticula: pathophysiology, clinical presentation, and flexible endoscopic management

L. E. V. V. C. Ferreira, D. T. Simmons, T. H. Baron

Division of Gastroenterology and Hepatology, Mayo Clinic College of Medicine, Rochester, Minnesota, US

SUMMARY. **Zenker's diverticulum (ZD) is the most common type of diverticulum in the upper gastrointestinal tract. Most patients are elderly and present with symptoms of dysphagia. Serious complications include aspiration and malnutrition. The most common treatments are open surgical diverticulectomy with or without cricopharyngeal myotomy and rigid endoscopic myotomy. Recently, cricopharyngeal myotomy using flexible endoscopes has been described as a treatment option for symptomatic ZD. In this article we describe the pathophysiology, clinical presentation and review the techniques and outcome following flexible endoscopic management of Zenker's diverticulum.**

KEY WORDS: **endoscopy, Zenker's diverticulum.**

INTRODUCTION

Zenker's diverticulum (ZD) was first described by Ludlow in 1769.[1] However, it was Friedrich Von Zenker who recognized ZD results from increased intrapharyngeal pressure.[2] ZD, also termed cricopharyngeal diverticulum and pharyngoesophageal diverticulum, is located proximal to the upper esophageal sphincter (UES) usually on the posterior hypopharyngeal wall.[3]

A tissue bridge composed of mucosa, submucosa, connective tissue, and muscle between the lumen of esophagus and diverticulum is present. Inadequate relaxation of the cricopharyngeal muscle leads to outflow obstruction creating a zone of high pressure in the hypopharynx. Fibrosis of muscle fibers and progressive tension over the esophageal wall results in formation of a diverticulum.[4]

The initial surgical approach was open diverticulectomy with or without performance of cricopharyngeal myotomy.[5] However, the endoluminal approach using rigid laryngoscopes has become the predominant surgical technique.[5,6]

Endotherapy using flexible endoscopes has evolved over the last 12 years.[7,8] In this review we will discuss various flexible endoscopic approaches and treatment outcomes for ZD.

Address correspondence to: Todd H. Baron, MD, 200 First St. SW, Charlton 8, Rochester, MN 55905, USA.
Email: baron.todd@mayo.edu

ANATOMY, ETIOLOGY AND PATHOPHYSIOLOGY

A complete understanding of the pathogenesis of ZD has not been reached despite a century of research. Several hypotheses have been proposed, all relating to a structural or physiological abnormality of the cricopharyngeal muscle.

There are inherent areas of weakness along the esophageal wall where diverticula can occur, particularly within the pharyngoesophageal segment. Killian's triangle, where ZD develops, is a potential space between the inferior pharyngeal constrictor muscle and the cricopharyngeus muscle. These two muscles form the pharyngoesophageal segment. Both muscles contribute to the high pressure zone; however, it is the cricopharyngeus muscle that is primarily responsible for the tone of the region. The cricopharyngeus muscle forms a muscular sling at the esophageal inlet, attaching to either side of the cricoid cartilage without a midline raphe. The inferior constrictor muscle extends from the oblique line of the thyroid cartilage to insert in the posterior midline pharyngeal raphe, a fibrous band extending from the base of the skull to which all of the constrictor muscles are attached. When present, Killian's dehiscence lies just above the cricopharyngeal sling, below the raphe (Fig. 1).[9,10]

Another area of weakness is the Killian-Jamieson area, where lateral or Killian-Jamieson diverticulum

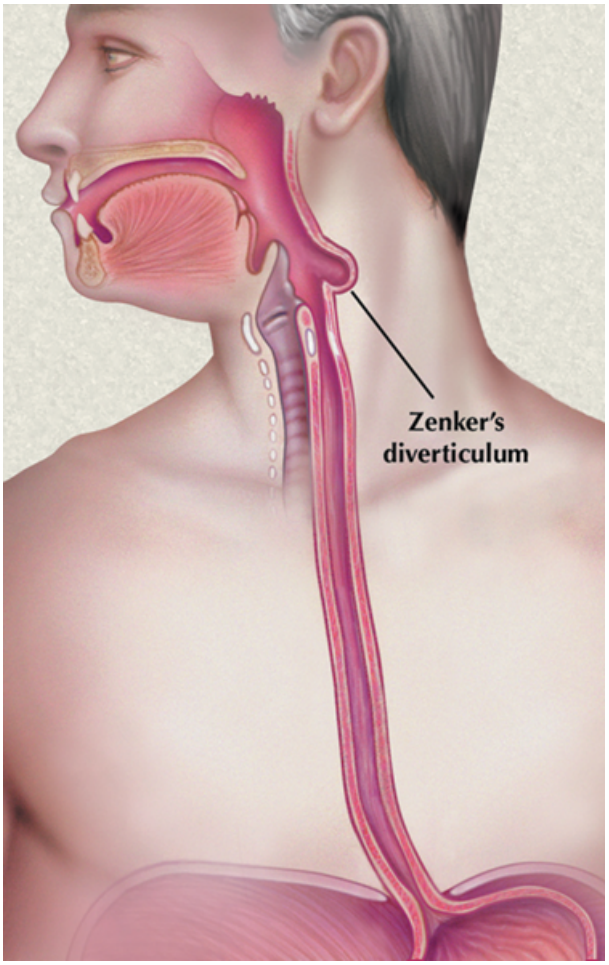

Fig. 1 Illustration of Zenker's diverticulum.

can be formed (Fig. 2).[9,10] It is important to differentiate this type of diverticulum from ZD[11] since the treatment approach is different.

In order for the pharyngeal pouch to be formed a high intrabolus pressure must occur to cause herniation through the weakened area. Achalasia or cricopharyngeal spasm, cricopharyngeal incoordination or congenital weakness have been implicated.[12,13] Because gastroesophageal reflux (GER) leads to cricopharyngeal spasm, it may have a role in ZD formation.[14]

A variety of abnormalities in UES function have been described such as increased pressure, decreased pressure, uncoordinated contraction, premature contraction and relaxation.[15–17] The most widely accepted theory is that UES relaxation is inadequate resulting in incomplete opening of the UES and high intrabolus pressure.[10,16,17] Histologically, the presence of inflammatory signals and development of fibrosis of the cricopharyngeus has also been demonstrated.[17]

CLINICAL FEATURES AND DIAGNOSIS

Zenker's diverticulum usually occurs between the seventh and eighth decades of life, and rarely before

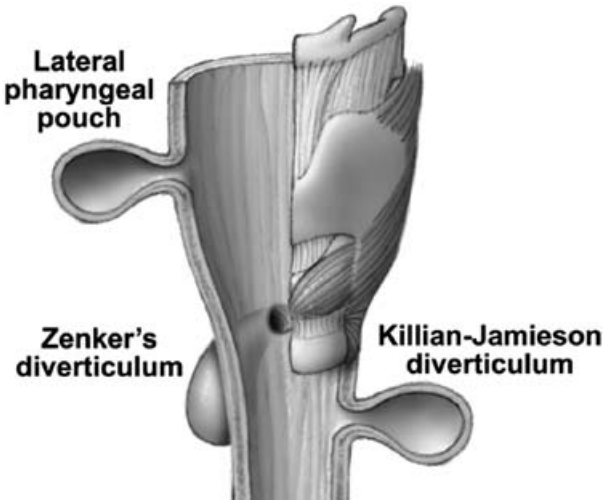

Fig. 2 Illustration showing the various types of upper esophageal diverticula.

the age of 40 years.[18] It occurs predominately in men. The prevalence of ZD among the general population is believed to be between 0.01% and 0.11%.[19] The incidence varies based on region, being more common in northern than southern Europe. It has been described more frequently in the US, Canada and Australia than in Japan and Indonesia.[20] Anatomical differences between geographic areas may contribute to differences in incidence.[21] In the UK, the incidence of ZD is about 2 per 100 000 people per year.[22] However, the true incidence of ZD is difficult to establish since the number of asymptomatic patients is unknown.

Although several symptoms may be present, 80–90% of patients complain of dysphagia. Regurgitation of undigested foods, halitosis, and hoarseness can also occur. Cervical borborygmi is almost pathognomonic of ZD.[10] As the pouch enlarges, symptoms become more severe with resultant weight loss and malnutrition.[23] As many as 30–40% of patients describe chronic cough and repeated episodes of aspiration, some with aspiration pneumonia. Symptoms may be present for weeks to several years.[23]

A sudden increase in the severity of dysphagia and regurgitation and/or development of alarm symptoms such as local pain and hemoptysis or hematemesis may signal the presence of squamous cell carcinoma within the ZD[24] which has an incidence of 0.4–1.5%.[10,25,26] Other pathologies associated with ZD include laryngocoele, leiomyoma, polymyositis, cervical esophageal web, carotid body tumor, anterior cervical fusion, stenosis of upper esophagus, hiatus hernia, and gastroesophageal reflux.[27] These coexisting pathologies are not directly associated with or caused by ZD, but can be additional causes of dysphagia in patients with ZD. Gastroesophageal reflux (GER) has been implicated in the genesis of ZD based upon the fact that ZD is very uncommon in countries where GER is rare.

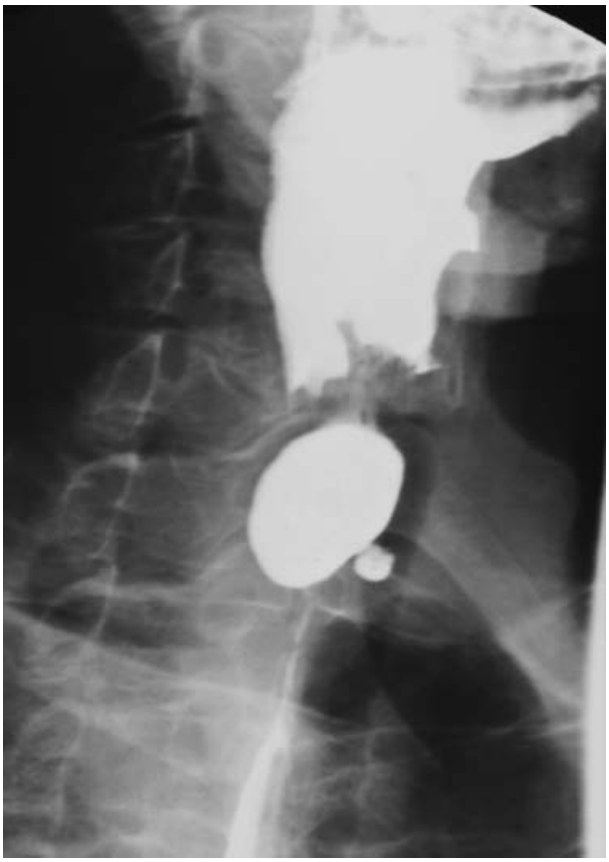

Fig. 3 Barium esophagram of Zenker's diverticulum obtained prior to undergoing successful flexible endoscopic therapy.

Physical examination findings are few and are usually seen in more severe cases. They include findings of malnutrition, voice changes, neck mass, cervical borborygmi and crepitus.[10,22]

In most cases, the diagnosis of ZD is suspected based on clinical symptoms and confirmed by barium esophagram (Fig. 3). Small diverticula can be missed if superimposed on the main column of barium in the esophagus, which is avoided by rotating the patient. ZD can be found incidentally in patients who undergo flexible upper endoscopy because of unrelated symptoms.

Complications of untreated ZD include retained foreign body and bezoar, tracheal fistula, vocal cord paralysis, fistula to the prevertebral ligament with cervical osteomyelitis, peptic ulceration, and hemorrhage.[27]

TREATMENT

Treatment for ZD is indicated for all symptomatic patients with or without associated complications. Exceptions to this are morbidly ill patients, those with small diverticulum, and those with minimal symptoms. ZD is a disease of elderly patients and it is important to consider the comorbid conditions, particularly Parkinson's disease (PD). PD patients have decreased pharyngeal contraction and may not clinically improve after cricopharyngeal myotomy.[28]

Flexible endoscopic treatment may be particularly advantageous for high-risk elderly patients who can benefit from a brief procedure without general anesthesia and without the need for hyperextension of the neck. Despite the recommendation by most authors to limit the procedure to high-risk, elderly patients, some centers offer the flexible endoscopic approach to all symptomatic patients referred for treatment.[6]

The principle of flexible endoscopic therapy for ZD is the division of the septum between the diverticulum and esophagus, within which the cricopharyngeus muscle is contained (cricopharyngeal myotomy). Several case series have demonstrated the efficacy and safety of cricopharyngeal myotomy using a flexible endoscopic approach.[29–36] With a flexible endoscopic approach the diverticulum often persists on follow-up radiographs despite relief of dysphagia. The division of the septum allows food and liquid to flow out of the diverticulum distally into the esophagus rather than to lodge within the diverticulum.[29,30]

Flexible endoscopic treatment of ZD may be performed in the outpatient or inpatient setting. When patients are admitted after the procedure for observation, the hospital stay is usually 24–48 h in the absence of complications. When performed completely in the outpatient setting, patients are closely observed for 6 h after the procedure before discharge from the endoscopy unit. Although there is no consensus on need for antibiotic prophylaxis, a single intravenous dose (ciprofloxacin 400 mg or ampicillin 2 g) is often administrated. Based on regional variation, patient preference, American Society of Anesthesiologists (ASA) status, the sedation may be moderate, deep, or with endotracheal intubation.

The goal of cricopharyngeal myotomy is to reduce the septum to less than a length of 1 cm in order to decrease UES pressure.[30,37] Manometric studies have demonstrated efficacy in reducing UES pressure after flexible endoscopic cricopharyngeal myotomy.[29]

While a variety cutting methods have been used to divide the septum, the use of coagulation currently predominates. There appears to be a correlation between the length of the incision and the need for repeat cricopharyngeal myotomy. Generally a 1.5–2.0 cm incision is performed in one session, which is adequate to treat small diverticula (= 2 cm). Larger diverticula (i.e. > 3 cm) may require longer incisions and repeat procedures.[6,30–32] The interval between sessions depends on the adequacy of the cricopharyngeal myotomy, ranging in the literature from 2 days to 3 months. The short intervals between sessions have been described using argon plasma coagulation (APC).[33]

Three principal techniques employed to cut the septum are: (i) needle-knife incision; (ii) APC; and

(iii) monopolar coagulation using forceps. The optimal technique is unknown, since prospective, randomized trials are lacking. The technique chosen is based upon endoscopist experience and preference. Each of these will be described.

Use of the needle-knife technique may be employed with different accessories (cap, hood, overtube) and is associated with a longer learning curve, but is an attractive approach for patients in whom an excellent view of septum can be obtained (Fig. 4)[38] The septum is dissected using blended current, alternating cut and coagulation mode, or a pure coagulation current.[31,34] The needle is advanced from the sheath and the tip is positioned at the top of the septum at its midpoint. An incision is created in a caudal direction, toward the inferior aspect of the diverticulum. The cut can be directed from the inside of the diverticulum toward the posterior esophageal wall or in the opposite direction. Some authors then routinely place endoclips at the base of the incision to prevent microperforation.[35]

The incision must not extend beyond the inferior border of the diverticulum as this leads to the mediastinal perforation. Unfortunately, this border can be difficult to define endoscopically. Too short an incision can lead to an incomplete cricopharyngeal myotomy and may account for the clinical recurrence rate of around 20% following flexible endoscopic therapy (Table 1).

When using APC one can either begin the incision 2–3 cm below the top of the bridge and extend upward or begin at the septum and extend downward.[33] High-power settings are used (APC 300 Erbe Generator at 99 watts and Erbe VIO-APC at 50 watts and APC mode 'pulsed 1') in a non-contact method.[33] Several authors describe limited incisions in a single session, with repeat procedures performed as early as 2 days. Small diverticula can easily be treated in one session using this method.

The forceps technique has only recently been described. In this report, a transparent hood was used to identify the septum.[38] Alligator spoon forceps or rat-tooth forceps are used to grasp the mid-portion of the top of the septum and the bridge gently pulled into the hood. The part of the Zenker bridge pulled into the hood was then cut using a blended current (cutting 120 watt maximum/coagulation 60 watt maximum) and repeated until the endoscope could be easily passed into the esophagus. Potential advantages of this technique include less patient discomfort, since the forceps and not the tip of endoscope is moved during the procedure. Tissue compression that occurs prior to coagulation may reduce the risk of bleeding.

Different cutting techniques using a variety of accessories (nasogastric tube, hood, endoscopic cap, and overtube) have been employed for flexible endoscopic treatment of ZD. Most endoscopists utilize a standard, large bore (18Fr) nasogastric (NG) tube in order to stabilize the anterior esophageal wall and protect it against thermal injury (Fig. 5).[30,32–34,36] The NG tube tip is cut to create an end hole and is inserted over a guidewire. The decision to remove the NG tube immediately after the procedure or to leave it in for a delayed period of time is based upon endoscopist preference.

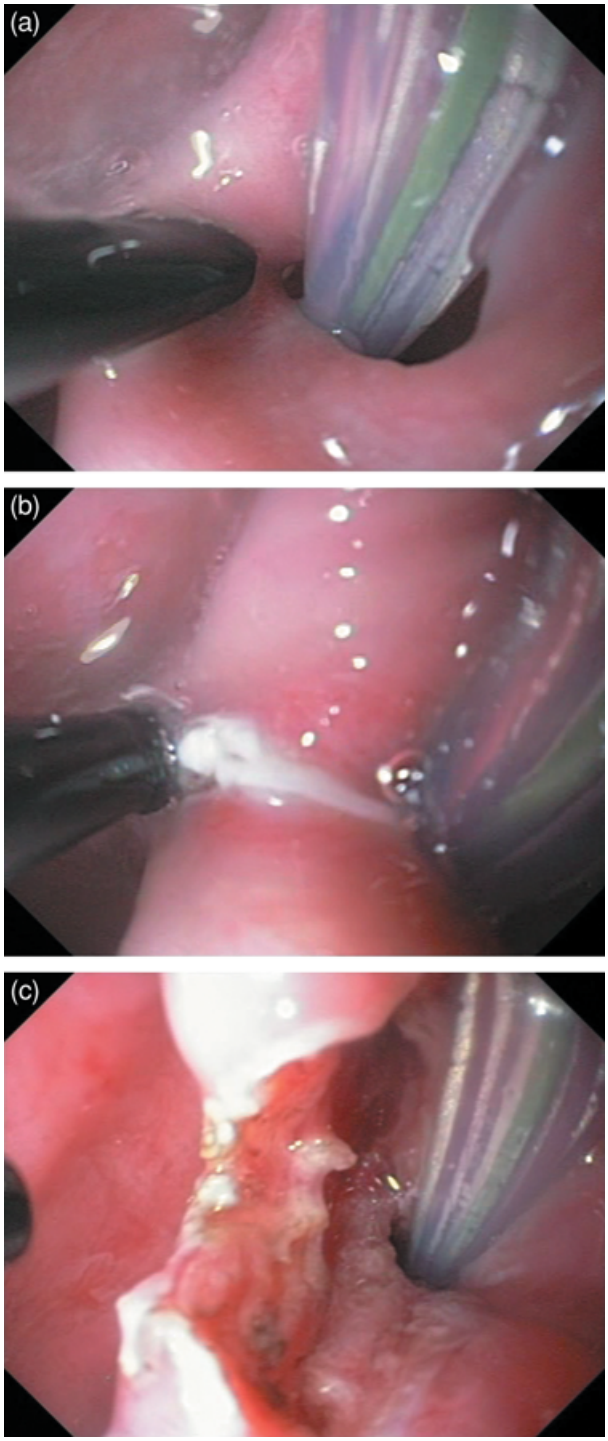

Fig. 4 Endoscopic view of needle-knife technique. (a) The needle knife is seen in the visual field; (b) after initial incision; (c) after complete incision.

Table 1 Reports of Zenker's diverticulotomy using flexible endoscopy

Author/year	*N*	Age in years (median)	Zenker's length (cm)	NGT guide	Endoscopic device	Incision	Emphysema†	Bleeding	Sessions mean (range)	Mean follow-up months	Recurrence	% clinical resolution rate
Mulder 1995	20	?	6 (2–12)	Yes	None	Forceps Coagulation	None	None	3 (1–12)	6.7 (1–24)	n.a.	n.a.
Ishioka 1995	42	68.4	4.2 (2–11)	Variable		Needle kife	1 (2%)	1 (2.4%)	1.8	38 (12–96)	3 (7.1%)	92.8%
Sakai 2001	10	67–87	3–5	No	Hood	Needle kife	None	None	1	n.a. (2–12)	None	100%
Hashiba 1999	47	58–81	2–10	Yes		Needle kife	6 (13%)	1 (2.1%)	1–4	n.a. (0–12)	n.a.	96%
Mulder 1999	125	77	4.5 (2–12)	Yes	None	APC	19 (15%)	2 (1.6%)	1.8 (1–12)	n.a.	n.a.	100%
Costamagna 2007 Cap	28	66	4 (2–8)	Yes	Cap	Needle kife	5 (18%)	4 (14%)	n.a.	36 (9–60)	8 (29%)	43%
Costamagna 2007 Diverticuloscope	11	70	4 (3–7.5)	No	Diverticuloscope	Needle kife	None	None	n.a.	6.5 (3–15)	1 (9%)	91%
Rabenstein 2007	41	73	n.a.	Yes	Cap	APC	1 (3%)	None	3 (2–10)	16 (6–43)	17%	95%
Christaens 2007	21	77.5	n.a.	Yes	Hood	Monopolar frceps	1 (4.8%)	None	1.1 (1–2)	23	10%	100%
Vogelsang 2007	31	69	3.7	Yes	Cap	Needle kife	7 (23%)	1 (3.3%)	1.4 (1–3)	26 (14–49)	35%	84%

NGT = nasogastric tube; †mediastinal or subcutaneous; n.a. = Not available; APC = agon plasma coagulation.

Fig. 5 Endoscopic view of nasogastric tube within the esophageal lumen which allows the septum to be defined.

Fig. 6 Photo of hood that attaches to a flexible endoscope for Zenker's treatment (Olympus Optical Company).

In 2001, Sakai *et al*. described attachment of an oblique-end transparent hood to the tip of the flexible endoscope (Fig. 6) (MH589; Olympus Optical Co., Ltd, Tokyo, Japan). This accessory optimizes exposure of septum, separating it from the anterior esophageal wall.[31] Two small series have been published using this device. No cases of bleeding have occurred and there was a very low rate of perforation (Table 1).

Another accessory employed for ZD treatment is a 'diverticuloscope' (Fig. 7) (ZD overtube, ZDO-22–30; Wilson-Cook, Winston-Salem, NC, USA) which consists of a soft rubber overtube with two distal flaps that protect the anterior esophageal and posterior diverticular walls and provide better exposure of the septum. In one retrospective study,



Fig. 7 Photo of the 'diverticuloscope' also known as the ZD overtube (ZDO-22–30; Cook endoscopy).

Costamagna *et al*. found that the 'diverticuloscope' made the procedure easier and safer when compared to the use of a hood.[37] Three factors were felt to account for this: (i) fixation of the septum; (ii) better exposure of the septum; and (iii) better protection of the anterior esophageal and posterior diverticular walls. Mucosectomy caps are generally used in the US since the diverticuloscope is not currently FDA-approved.

Assuming no complications, liquids are introduced 12 h post-procedure and advanced to soft and then regular food over the next 24–48 h as tolerated.

COMPLICATIONS

Complications following flexible endoscopic therapy of ZD include those related to sedation, aspiration, perforation, and bleeding. Throat pain is not uncommon and should be anticipated. Perforation can range from subcutaneous or mediastinal emphysema to cervical abscess (Fig. 8) and mediastinitis. If overt perforation is identified during the endoscopic procedure, immediate closure using endoclips can be attempted. A post-procedural chest CT scan and surgical consultation are appropriate.

Uncomplicated cervical or mediastinal emphysema occurs in 0–23% of patients (Table 1, Fig. 9) and likely represents microperforation. The air generally resolves within 2–5 days.[33,35] Most endoscopists routinely obtain a postprocedural chest X-ray to assess for the presence of mediastinal air. If pneumomediastinum occurs, a chest CT scan with oral contrast should be obtained. In a clinically stable patient without overt fluid in the mediastinum or leakage of contrast by CT scan, conservative management with administration of antibiotics and withholding of oral intake can be undertaken. Delayed development of fever, tachycardia, leukocytosis, cervical or mediastinal emphysema should be evaluated with chest CT scan to identify perforation and the presence of mediastinal fluid. In any patient the presence of mediastinal fluid on CT scan warrants surgical consultation.

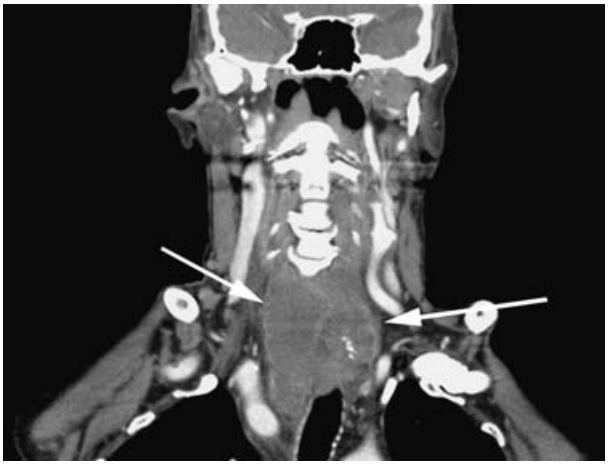

Fig. 8 Coronal CT image of the neck in a patient who underwent seemingly uncomplicated flexible endoscopic therapy of a Zenker's diverticulum 2 weeks prior. A large cervical abscess is identified (arrows). Surgical drainage was required.

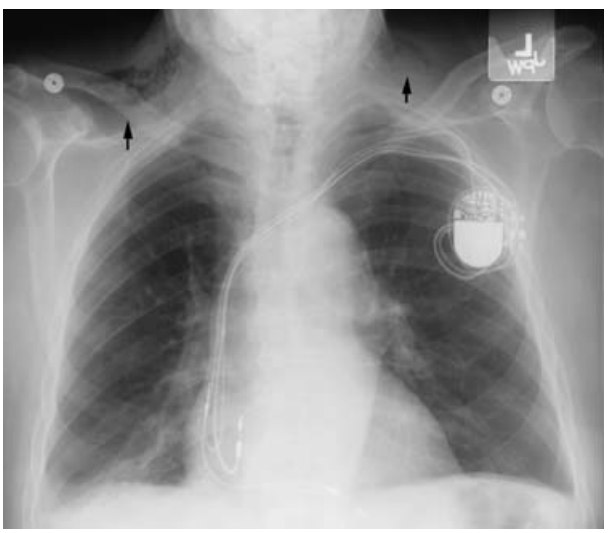

Fig. 9 Chest X-ray following flexible endoscopic therapy of a Zenker's diverticulum. Cervical subcutaneous emphysema is seen (arrows). Note absence of mediastinal air. The patient did well with conservative treatment.

Fever with leukocytosis but without evidence of perforation or mediastinitis may occur.[33] In this case, antibiotics are administered and continued empirically until disappearance of fever and normalization of white blood cell count. Isolated fever lasting less than 24 h without evidence of infection is common after APC treatment, perhaps as a result of thermal injury.[33]

Some authors routinely obtain post-procedural water-soluble contrast esophagograms though it has limited sensitivity for detection of small perforations, and does not correlate with symptomatic response to endoscopic therapy.[39]

Bleeding occurs in 0–10% of patients following endoscopic cricopharyngeal myotomy (Table 1). Intra-procedural bleeding can be treated by electrocoagulation using the needle-knife tip, hot biopsy

forceps, APC probe[34] injection of dilute epinephrine, and/or application of endoclips. In those patients who are not endotracheally intubated, precaution should be taken to prevent aspiration. Delayed bleeding can be managed endoscopically using dilute epinephrine injection, electrocoagulation methods, and endoclip placement.

TREATMENT RESULTS AND OUTCOMES

Table 1 shows the endoscopic methods, number of treatment sessions required, and success and recurrence rates. The results suggest that outcomes of the different endoscopic approaches are relatively similar, though it appears that APC treatment is associated with more endoscopic sessions. Success following flexible endoscopic therapy is defined as a decrease in frequency and severity of symptoms, not radiographic changes, since diverticula often persist despite symptom relief. Because different dysphagia scores have been used to define success and recurrence, it is difficult to make comparisons between endoscopic treatment approaches.

SUMMARY

Treatment options for ZD include open surgical, rigid endoscopic, and most recently, flexible endoscopic therapy. Flexible endoscopic therapy involves severing the cricopharyngeal muscle which appears endoscopically as a septum between the diverticulum and the esophageal lumen. Flexible endoscopic therapy differs from rigid endoscopic therapy in several ways. Rigid therapy is usually performed by ENT surgeons in the operating room under general anesthesia and requires hyperextension of the neck. The myotomy is performed with stapling devices, although CO_2 laser division has also been used. Flexible endoscopic therapy has been performed by gastroenterologists using standard flexible endoscopic instruments in endoscopy suites with moderate sedation, monitored anesthesia care, or general anesthesia. The myotomy is performed using electrocautery. Advantages of this technique are the ability to perform the procedure without general anesthesia or neck hyperextension, ability to treat smaller diverticula,[40] and the rapid resumption of oral intake. Since the procedure is usually performed in the endoscopic unit and frequently in an outpatient setting, it may be associated with a decrease in overall procedural costs.

The experience to date using flexible endoscopic therapy is promising. Although early reports focused on the use of endoscopic therapy for poor operative candidates, some centers now offer endoscopic therapy for all symptomatic patients, regardless of surgical candidacy. The current data suggests that flexible endoscopic therapy for ZD results in symptomatic improvement with low recurrence rates and acceptable complication rates. Ideally, comparative studies of flexible endoscopic methods to rigid endoscopic methods would help to determine the optimal treatment for symptomatic patients with Zenker's diverticula.

References

1 Ludlow A. A case of obstructed deglutition from a preternatural dilatation of and bag formed in the pharynx. Medical Observations and Enquiries by a Society of Physicians in London, 2nd edn. 1769; 3: 85–101.
2 Zenker F A, von Ziemssen H. Krankheiten Des Oesophagus. In: von Ziemssen H, (ed.). Handbuch der Speciellen Pathologie and Therapie, Vol. 7 (Suppl). Leipzig: FCW Vogel, 1877; 1–87.
3 Wouters B, Van Overbeek J J M. Pathogenesis and endoscopic treatment of the hypopharyngeal (Zenker's) diverticulum. Acta Gastroenterol Belg 1990; 53: 323–9.
4 Peters J H, Mason R. The physiopathological basis for Zenker's diverticulum. Chirurg 1999; 70: 741–6.
5 Gutschow C A, Hamoir M, Rombaux P, Otte J B, Goncette L, Collard J M. Management of pharyngoesophageal (Zenker's) diverticulum: which technique? Ann Thorac Surg 2002 Nov; 74: 1677–82; discussion 1682–3.
6 Costantini M, Zaninotto G, Rizzetto C, Narne S, Ancona E. Oesophageal diverticula. Best Pract Res Clin Gastroenterol 2004 Feb; 18: 3–17.
7 Mulder C J, den Hartog G, Robijn R J, Thies J E. Flexible endoscopic treatment of Zenker's diverticulum: a new approach. Endoscopy 1995 Aug; 27: 438–42.
8 Feussner H. Endoscopic therapy for Zenker diverticulum – the good and the bad. Endoscopy 2007 Feb; 39: 154–5.
9 http://famo.erbak.com/OTOHNS/Paparella/pap0338.pdf. Allen M. Seiden.
10 http://www.bcm.edu/oto/grand/05-06-04.htm. Zenker's Diverticulum. Christopher Prichard, M.D. May 6, 2004.
11 Rubesin S E, Levine M S. Killian-Jamieson diverticula: radiographic findings in 16 patients. AJR Am J Roentgenol 2001 Jul; 177: 85–9.
12 Sutherland H D. Cricopharyngeal achalasia. J Thorac Cardiovasc Surg 1962 Jan; 43: 114–26.
13 Belsey R. Functional disease of the esophagus. J Thorac Cardiovasc Surg 1966 Aug; 52: 164–88.
14 Veenker E A, Andersen P E, Cohen J I. Cricopharyngeal spasm and Zenker's diverticulum. Head Neck 2003; 25: 681–94.
15 Fulp S R, Castell D O. Manometric aspects of Zenker's diverticulum. Hepatogastroenterology 1992 Apr; 39: 123–6.
16 Cook IJ, Gabb M, Panagopoulos V *et al*. Pharyngeal (Zenker's) diverticulum is a disorder of upper esophageal sphincter opening. Gastroenterology 1992 Oct; 103: 1229–35.
17 Cook I J, Blumbergs P, Cash K, Jamieson G G, Shearman D J. Structural abnormalities of the cricopharyngeus muscle in patients with pharyngeal (Zenker's) diverticulum. J Gastroenterol Hepatol 1992 Nov–Dec; 7: 556–62.
18 Maran A G D, Wilson J A, Al Muhanna A H. Pharyngeal diverticula. Clin Otolaryngol 1986; 11: 219–25.
19 Watemberg S, Landau O, Avrahami R. Zenker's diverticulum: reappraisal. Am J Gastroenterol 1996; 91: 1494–8.
20 van Overbeek J J, Groote A D. Zenker's diverticulum. Curr Opin Otolaryngol Head Neck Surg 1994; 2: 55–8.
21 van Overbeek J J. Pathogenesis and methods of treatment of Zenker's diverticulum. Ann Otol Rhinol Laryngol 2003 Jul; 112: 583–93.
22 Siddiq M A, Sood S, Strachan D. Pharyngeal pouch (Zenker's diverticulum). Postgrad Med J 2001 Aug; 77: 506–11.
23 Bowdler D A. Pharyngeal pouches. In: Kerr A, (ed.). Scott Brown's Textbook of Otorhinolaryngology, 6th edn. Oxford: Butterworth-Heinmann, 1997; 1–21.
24 Huang B S, Unni K K, Payne W S. Long-term survival following diverticulectomy for cancer in pharyngoesophageal (Zenker's) diverticulum. Ann Thorac Surg 1984; 38: 207–10.

25 Bradley P J, Kochaar A, Quraishi M S. Pharyngeal pouch carcinoma: real or imaginary risks? Ann Otol Rhinol Laryngol 1999; 108: 1027–32.
26 Bowdler D A, Stell P M. Carcinoma arising in posterior pharyngeal pulsion diverticulum (Zenker's diverticulum). Br J Surg 1987 Jul; 74: 561–3.
27 Sen P, Kumar G, Bhattacharyya A K. Pharyngeal pouch: associations and complications. Eur Arch Otorhinolaryngol 2006 May: 263 (5): 463–8 Epub 2006 Feb 4.
28 Achem S R, Devault K R. Dysphagia in aging. J Clin Gastroenterol 2005; 39: 357–71.
29 Ishioka S. Endoscopic incision of Zenker's diverticula. Endoscopy 1995; 27: 433–7.
30 Mulder C J J. Zapping Zenker's diverticulum: gastroscopic treatment. Can J Gastroenterol 1999; 13: 405–7.
31 Sakai P, Ishioka S, Maluf-Filho F, Chaves D, Moura E G H. Endoscopic treatment of Zenker's diverticulum with an oblique-end hood attached to the endoscope. Gastrointest Endosc 2001; 54: 760–3.
32 Hashiba K, de Paula AL, da Silva JG *et al*. Endoscopic treatment of Zenker's diverticulum. Gastrointest Endosc 1999; 49: 93–7.
33 Rabenstein T, May A, Michel J *et al*. Argon plasma coagulation for flexible endoscopic Zenker's diverticulotomy. Endoscopy 2007 Feb; 39: 141–5.
34 Vogelsang A, Preiss C, Neuhaus H, Schumacher B. Endotherapy of Zenker's diverticulum using the needle-knife technique: long-term follow-up. Endoscopy 2007 Feb: 39: 131–6 Epub 2006 Oct 16.
35 Costamagna G, Iacopini F, Tringali A *et al*. Flexible endoscopic Zenker's diverticulotomy: cap-assisted technique vs. diverticuloscope-assisted technique. Endoscopy 2007 February; 39: 146–52.
36 Christiaens P, De Roock W, Van Olmen A. Moons V, D'Haens G. Treatment of Zenker's diverticulum through a flexible endoscope with a transparent oblique–end hood attached to the tip and a monopolar forceps. Endoscopy 2007 Feb; 39: 137–40.
37 Dohlman G, Mattson O. The endoscopic operation for hypopharyngeal diverticula. Arch Otolaryngol 1960; 71: 744–52.
38 Mulder C J J. Zenker's Diverticulum. UpToDate 2007.
39 Witterick I J, Gullane P J, Keller M A. Postoperative carotid body tumor evaluation: analysis using MR angiography. Laryngoscope 1995 Jul; 105: 764–7.
40 Sakai P. Endoscopic treatment of Zenker's diverticulum. Gastrointest Endosc 2007; 65: 1054–5.