



FACULDADE DE MEDICINA DA UNIVERSIDADE DE COIMBRA
MESTRADO INTEGRADO EM MEDICINA – TRABALHO FINAL

MARTA GARCIA COSTA

***JUVENILE OSSIFYING FIBROMA COMPROMISING THE ZINN'S
ANNULUS***

CASO CLÍNICO

ÁREA CIENTÍFICA DE OTORRINOLARINGOLOGIA

Trabalho realizado sob a orientação de:

JOÃO CARLOS RIBEIRO

MAFALDA DA SILVA FERREIRA

ABRIL/2018

JUVENILE OSSIFYING FIBROMA COMPROMISING THE ZINN'S ANNULUS

Marta Garcia Costa¹, Mafalda da Silva Ferreira², João Carlos Ribeiro^{1,2}

¹Faculty of Medicine, University of Coimbra, Portugal

²Department of Otorhinolaryngology, Centro Hospitalar e Universitário de Coimbra,
Portugal

Contact: marta.gcosta@hotmail.com

Abstract

Juvenile ossifying fibroma is a rare fibro-osseous neoplasm that mainly affects the bones of the orbit and paranasal sinuses. Although benign, it presents a locally aggressive behavior and a high relapse rate. In specific locations, it poses a great treatment challenge so that early diagnosis and multidisciplinary treatment are crucial to improve the prognosis and delay clinical sequelae.

Sinuses and medial orbit neoplasms diagnosis is made from clinical, imaging and histopathological exams. CT-scans and preoperative biopsy play an important role. The treatment of choice is a surgical resection. Endoscopic nasal approach is recommended because of its lower morbidity. However, there are some cases in which other options must be considered to perform resection as complete as possible and preserve function.

We report a case of a young woman with psammomatoid type juvenile ossifying fibroma of the medial aspect of the Zinn's annulus, undergoing surgical optic nerve decompression, combining a transcranial bicoronal open and endonasal endoscopic surgery.

Functional success in clinical practice dealing with juvenile ossifying fibroma of the orbit is associated to a rigorous preoperative planning, multidisciplinary approach, and the use of the most appropriate techniques for each case, depending mostly on the characteristics of the tumor, especially size and location.

Keywords: Paranasal Sinus Neoplasms; Fibroma, Ossifying; Natural Orifice Endoscopic Surgery; Rhinosurgery

Introduction

Juvenile Ossifying Fibroma (JOF), a variant of Ossifying Fibroma (OF), is a rare benign fibro-osseous neoplasm that is divided into two subgroups, the trabecular and the psammomatoid, distinguished by clinical and histological characteristics. Pathogenesis mechanisms are still not completely understood.^{1,2} It can present a fast growth with high vascularization,² with destruction of the adjacent structures, resulting in important loco-regional destruction. It is characterized by an early age appearance, usually ranging between 5 and 15 years, and a slightly male preference.³ It mainly affects the orbital bones and paranasal sinuses.^{3,4}

The optic canal, with 10mm length, contains the optic nerve, ophthalmic artery and sympathetic plexus.⁵ The optic nerve is ensheathed in all three meningeal layers in its extracranial portion, as an extension of the brain, when damaged may result in irreversible blindness. It can be anatomical divided in possible sites of injury, intracanalicular is the most vulnerable to external compression.^{5,6}

JOF signs and symptoms depend on its location and size, ranging from nasal obstruction, rhinorrhea, epiphora, to exophthalmia, diplopia and facial dysmorphisms.^{2,3}

Differential diagnosis of JOF is made with traumatic optic neuropathy, inflammatory conditions, idiopathic intracranial hypertension,^{5,6} osteomas and fibrous intraosseous lesions such as fibrous dysplasia, desmoplastic fibroma, central giant cell granuloma and cherubism.⁷ A correct differentiation is critical because the treatments protocols are entirely different in some cases.⁸

Imaging plays an important role, not only in JOF diagnosis, but also for a more reliable preoperative evaluation, determination of possible anatomical variations,⁹ preparing the neuronavigation surgical aid and follow-up. CT-scan is the gold-standard to detect and stipulate the tumor's size. MRI imaging is recommended for ruling out cerebral or orbital invasion.²

JOF presents a high rate of recurrence, so it is essential to obtain an early diagnosis and treatment.^{7,10} In CT imaging, it presents as a lesion predominantly of soft tissues, well circumscribed with calcifications. In MRI, it exhibits low/medium intensity signal with enhancement after injection of contrast (gadolinium). Histologically, it is characterized by the presence of proliferative fibrous cell tissue and irregular osteoid strands containing osteoblasts with a broad variation of mineralization. The psammomatoid variant presents rounded calcifications called psammomatoid bodies.¹¹

Definitive diagnosis is made by the correlation between clinical, imagiological and histopathological findings.^{3,8,11} Whenever possible, a preoperative biopsy should also be performed.¹⁰

Treatment of choice is surgical, aiming the total removal of the tumor to avoid future relapses. Endoscopic endonasal surgery represents the first line since it allows good exposure in a minimally invasive manner, reducing morbi-mortality rates.¹² Despite the evolution in surgical techniques, it still presents a high rate of recurrence. Although there are no reported cases of malignant transformation or metastasis¹³, radiation therapy is not indicated and may increase the risk of malignancy and potential harmful late effects.^{2,13,14}

We report a case of a 26-year-old girl with a psammomatoid type recurrent JOF who underwent optic nerve decompression via a combined endoscopic endonasal and transcranial open approach with good clinical outcome.

Case report

A previously healthy 26-year-old Caucasian female presented to the emergency department exhibiting first time intense headaches in 2013. She was studied and a cranial MRI was performed revealing a 65 mm sphenoidal neoplasm.

After joint clinical decision, she underwent surgical treatment by a combined endonasal endoscopic and open transcranial approach, with subcomplete resection of the Zinn annulus lesion, resulting in a complete symptomatic resolution. Through a binostril approach, it was performed a complete sphenoidal neurectomy. The uncinata process was removed, and a middle meatal antrostomy provided access to the inferior and medial orbital walls. After the removal of the lamina papyracea, the optic canal was exposed in an antero-posterior direction, up to the lateral edge of the tuberculum sellae, by a dissector and gentle but extensive drilling with diamond burrs.

Optic carotid recess and latero-superior aspect of optic canal were not reachable. Histopathological findings indicated psammomatoid JOF (figure 1).

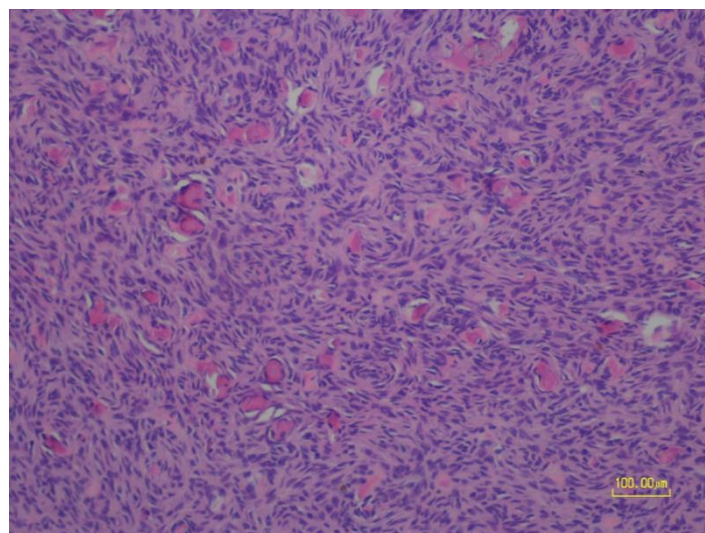


Figure 1: Optic microscopic view of patient's biopsy sample showing proliferative fibrous cell tissue containing rounded calcifications resembling psammomatoid bodies.

The patient returned one year later complaining of diplopia, presenting papilledema and right proptosis that resolved with systemic corticotherapy.

In 2016, she reported a progressive decrease in the right visual acuity, diplopia, and exhibited an afferent pupillary defect and chromatic alteration of reds. MRI imaging confirmed a neoformation centered on the ethmoid-frontal region growing into the naso-ethmoidal surgical cavity, with 6.2 cm in diameter, extending to the base of the skull and involving the right orbit (figure 2). The same combined approaches via open bifrontal craniotomy and endoscopic endonasal surgery were used, with optic nerve subtotal decompression. Transcranial complementary route was performed to achieve the decompression of the supero-lateral segment of the optic canal. Sphenoidectomy was widened after a large posterior septectomy with exposure of the optic canal up to the lateral edge of the tuberculum sellae (figure 3). The medial aspect of the optic nerve was uncovered till the annulus of Zinn.

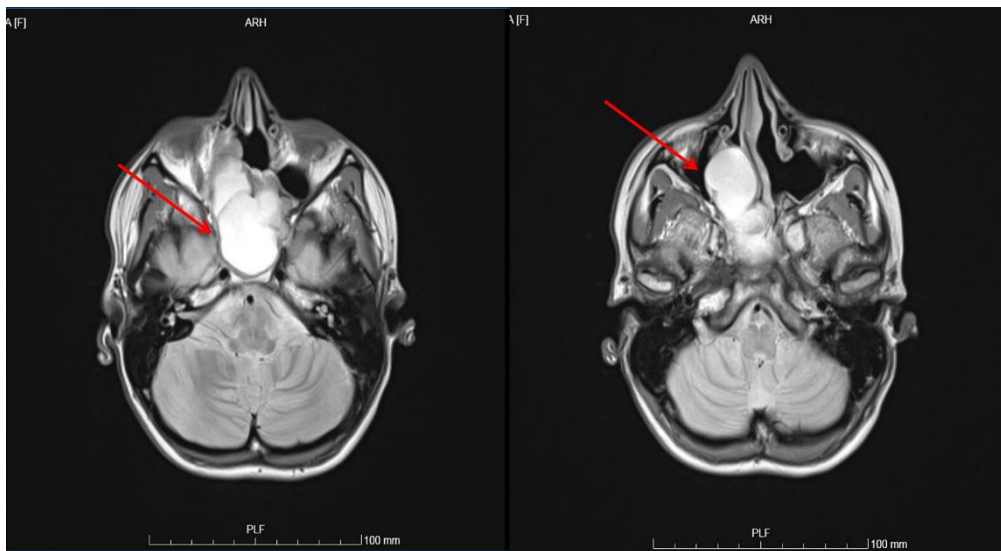


Figure 2: Pre-operative contrasted MRI of the perinasal sinuses presenting a tumor lesion affecting frontal and ethmoidal sinuses with extension to the skull base without involving the dura mater. Equally observed extension of the tumor into the apical side of the optic nerve (red arrows).

She was discharged on the 7th day of hospitalization, with no focal neurological symptoms. Visual acuity was maintained and no papilledema, signs of CSF fistula, headache or epistaxis were present.

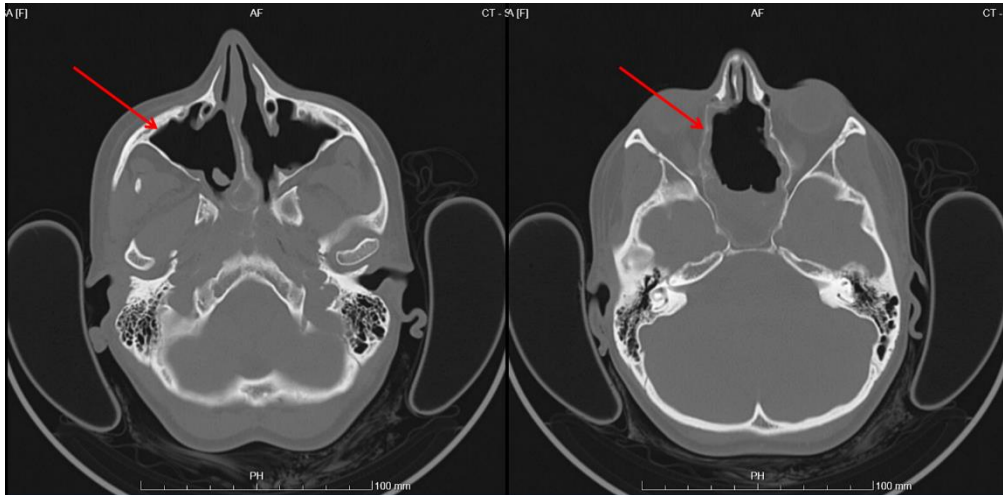


Figure 3: Postoperative CT of the orbits showing evidence of bilateral maxillary and ethmoidal sinusotomy (red arrows).

Patient maintains a regular follow-up with otorhinolaryngology, ophthalmology and neurosurgery. After 24 months, she is currently asymptomatic.

Informed consent was obtained from the patient.

Discussion

Juvenile ossifying fibroma involving the orbit nerve is a rare, potentially facial disfiguring, visual impairment and fatal tumor that requires a multidisciplinary individual treatment decision according to each patient and tumor location.

JOF may exhibit the trabecular or the psammomatoid histological pattern, the case reported here is compatible with the psammomatoid type. Definite diagnosis can be challenging but is crucial to guide the treatment.

The only current and first-line curative treatment is complete surgical excision of the lesion preferably by endonasal endoscopy. This approach provides an excellent visualization of the operative field, preservation of the olfactory function, avoidance of cosmetic morbidity and also avoidance of brain retraction, allowing lesion's total resection most of the times.¹⁵

Endonasal endoscopic surgery, although representing a low morbidity option and adequate exposure of the medial aspects of orbital apex, still presents complications, such as nasal sinus hemorrhage, rhinorrhea, subcutaneous emphysema and visual deterioration.⁶ Guided imaging systems revolutionized endoscopic surgery by minimizing operative time and the possibility of hemorrhage through better visualization of tumor margins.⁴

However, in cases such as the one described, due to the location and expansion of the tumor, a combined approach should be considered.¹⁰ Particularly in cases affecting the anterior wall of the frontal sinus or supraorbital recess, encasing the optic nerve or invading the skull base, an external approach is often needed. Contribution of other specialties, such as ophthalmology and neurosurgery, may be necessary in order to facilitate resection, decrease the likelihood of sequelae and reduce patient's recovery time. Optic nerve decompression is usually indicated if continuity of the nerve is not disrupted and there's evidence of worsening of visual acuity. It must be considered early in the disease to prevent nerve atrophy and its consequences.^{5,12}

Optic nerve decompression surgery can present some challenges such as the close relationship of the optic nerve and the paracavernous internal carotid artery that may limit the access.⁶ Another difficulty is the possible variation of the ophthalmic artery's position within the canal that requires caution when incising the optic nerve sheath.⁵ Also, the degree of sphenoid sinus pneumatization influences the amount of bone removal from the optic canal and even when it's feasible to access and decompress from its medial aspect, extensive drilling is required. A high-speed drill shaft can cause alar burns if prolonged manipulation so it is critical to use abundant irrigation to avoid thermal damage to the nerve.^{5,6}

The chosen approach will depend essentially on the location and size of the tumor. It should be emphasized the need of advanced technical expertise and experience and awareness of unpredictable intra-operative findings that may demand conversion of endoscopic into an open procedure.¹⁵

Prognosis is still uncertain, it is known that more aggressive lesions are less common in adults but there is still a high rate of relapse, so a wide excision and, if necessary, additional reconstructive surgery is recommended in order to preserve the functionality and aesthetics.⁴ Rigorous long-term follow-up should be performed even in the absence of any neurologic deficit.

Conclusion

Juvenile Ossifying Fibroma (JOF) is a rare benign fibro-osseous neoplasm, classified as a variant of ossifying fibroma, that occurs at earlier ages. It presents locally aggressive behavior and high rate of relapse. Radical resection surgery is widely considered the treatment of choice.

Endonasal endoscopic surgery currently represents the safest and most effective treatment, being minimally invasive and intended to restore function in inferior and medial JOF optic nerve tumors. In cases of optic nerve non-traumatic compression, it must be performed earlier in order to prevent nerve atrophy. The use of imaging exams (CT) for preoperative planning and use of navigation systems allows surgical technique optimization and risk minimization.

We conclude that a successful management of difficult cases of JOF requires a multidisciplinary teamwork, strict preoperative planning and the use of the most adequate and advanced surgical techniques. This way it is possible to avoid future relapses, ensure function and thus provide significant improvement in the patient's quality of life.

Acknowledgments

A particular acknowledgment to Professor Doutor João Carlos Ribeiro and Dr.^a Mafalda Ferreira for their guidance and readiness through this process. Their advice and support made this work possible. A word of appreciation to Dr.^a Maria José Abreu Julião for providing the data concerning the patient's histological sample.

A special word of acknowledgment to my family and friends that always believe in me and encourage me to do better, no matter the obstacles. I warmly thank them for being present in each and every one of the steps that made this long journey so rewarding. To my parents, with all my heart, huge thanks for their love and wisdom through the years.

References

1. Shields JA, Peyster RG, Handler SD, Augsburger JJ, Kapustiak J. Massive juvenile ossifying fibroma of maxillary sinus with orbital involvement. *British Journal of Ophthalmology*. 1985;69:392–395.
2. Ledderose GJ, Stelter K, Becker S, Leunig A. Paranasal ossifying fibroma: Endoscopic resection or wait and scan? *European Archives of Otorhinolaryngology*. 2011;268:999–1004.
3. Kubbi JR, K NK, Reddy V, Ramlal G. Juvenile Ossifying Fibroma. *Journal of Dental Sciences and Research*. 2011;2(2):1–5.
4. Hachach-Haram N, Benyon S, Maling S, Joshi N, Grant WE, Kirkpatrick WNA. Surgical management of two complex cases of large juvenile orbital ossifying fibroma. *Journal of Plastic, Reconstructive & Aesthetic Surgery*. 2011;64:1661–1664.
5. Lanisnik B, Ravnik J. Endoscopic Transnasal Optic Nerve Decompression. In: *Atlas of Otolaryngology , Head & Neck Operative Surgery.*; 2008:1–8.
6. Vescan AD, Carrau RL, Snyderman CH, Kassam AB. [Optic nerve decompression]. In: *Operative Techniques in Otolaryngology - Head and Neck Surgery*. Vol 2.; 2008:955–960.
7. Paiva JG, Boing F, Benaglia MB, Nascimento A. Fibroma Ossificante : relato de 2 casos Fibroma Ossifying : Report of 2 Cases. *Revista de Cirurgia e Traumatologia Buco-Maxilo-Facil*. 2009;9:33–40.
8. Nair SN, Kini R, Rao PK, Bhandarkar GP, Kashyp RR, Rai M, Naik N, Santhosh A. Fibrous dysplasia versus juvenile ossifying fibroma: A dilemma. *Case Reports in Dentistry*. 2016;2016.
9. Dafalla SE, Seyed MA, Elfadil NA, Elmustafa OM. A Computed Tomography-Aided

- Clinical Report on Anatomical Variations of the Paranasal Sinuses. 2017;6(2):24–33.
10. Appiani MC, Publique A, Paris H De, Publique A, Paris H De, Publique A, Paris H De, Publique A, Paris H De, Sciences M. Ossifying fibromas of the paranasal sinuses : diagnosis and management. *Acta Otorhinolaryngologica Italica*. 2015;35:355–361.
 11. Khoury NJ, Naffaa LN, Shabb NS, Haddad MC. Juvenile ossifying fibroma: CT and MR findings. *European Radiology*. 2002;12(SUPPL. 3):109–113.
 12. Berhouma M, M.Sc., Jacquesson T, M.Sc., Abouaf L, M.Sc., Vighetto A, Ph.D., Jouanneau E. Endoscopic endonasal optic nerve and orbital apex decompression for nontraumatic optic neuropathy: surgical nuances and review of the literature. *Neurosurgical Focus*. 2014;37(4).
 13. Sarode SC, Sarode GS, Waknis P, Patil A, Jashika M. Juvenile psammomatoid ossifying fibroma: A review. *Oral Oncology*. 2011;47(12):1110–1116.
 14. MD KB, Naseri I, Aldana P, Goldstein J, Jesehson G. *Juvenile Ossifying Fibroma : Successful Endoscopic Gross Total Resection of a Rare Sinonasal Tumor in an Adolescent Male.*; 2011.
 15. Carrau RL, Kassam AB, Snyderman CH, Duvvuri U, Mintz A, Gardner P. Endoscopic transnasal anterior skull base resection for the treatment of sinonasal malignancies. *Operative Techniques in Otolaryngology - Head and Neck Surgery*. 2006;17(2):102–110.