

COMMENTARY

Commentary: An Update to the new Coimbra Method for Recording Enthesal Changes

C. Y. HENDERSON,^{a*} C. WILCZAK^b AND V. MARIOTTI^c

^a CIAS – Research Centre for Anthropology and Health, Department of Life Sciences, University of Coimbra, Coimbra, Portugal

^b Department of Anthropology, San Francisco State University, San Francisco, CA USA

^c Laboratorio di Bioarcheologia ed Osteologia Forense, Dip. BiGeA, Alma Mater Studiorum Università di Bologna, Italy and ADÉS, UMR 7268 CNRS/Aix-Marseille Université/EFS, Marseille, France

Key words: biceps brachii insertion; bicipitoradial bursa; radial tuberosity

The radial tuberosity encompasses two anatomical structures: the enthesis of the biceps brachii insertion and the footprint of the bicipitoradial bursa (Chew and Giuffrè, 2005). Anatomical descriptions of the size of the biceps brachii enthesis footprint vary from only a couple of millimetres in width to covering an area of around 3 cm² (Chew and Giuffrè, 2005; Mazzocca et al., 2007; Forthman et al., 2008; Nolte and Wilczak, 2013). Differentiating these two footprints on skeletal remains using visual macroscopic methods is difficult. Furthermore, changes often occur across the radial tuberosity. For these reasons, the working group on methodology decided to amend the description of the extent of zone 2 from that of the original method paper (Henderson et al., 2013) to include the full radial tuberosity (Figure 1(a)). This should reduce interobserver error caused by recording different extents of the enthesis and should be easier to apply to skeletons.

In the biceps brachii attachment textural change can be seen both as the granular change described for the new method (Henderson et al., 2015) but also has vertically aligned fibres giving a striated appearance (Figure 1(b)). This latter change is seen more

commonly at this enthesis than the granular change. This striated textural change should therefore also be recorded under the heading textural change. The new definition for textural change now reads: A non-smooth, diffuse granular texture (with the appearance

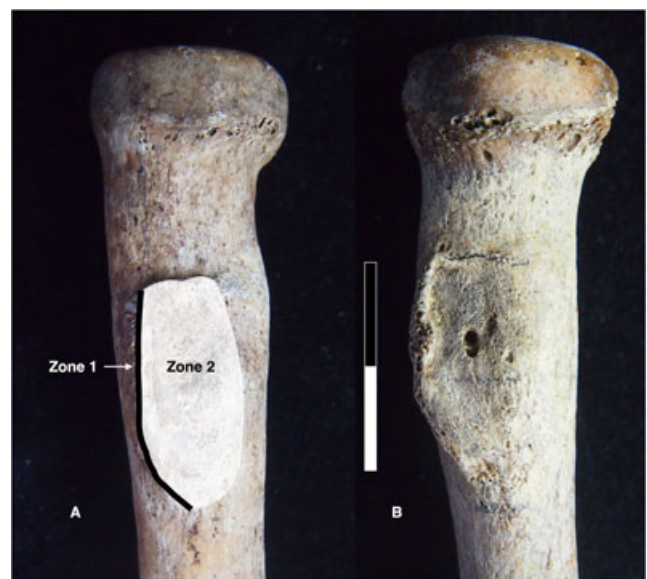


Figure 1. (a) Zones 1 and 2 for the biceps brachii insertion. (b) Example of striated textural change most obvious on the inferior half below the macropore. With thanks to the Department of Life Sciences, University of Coimbra for access to their collections to photograph.

* Correspondence to: C. Y. Henderson, CIAS – Research Centre for Anthropology and Health, Department of Life Sciences, University of Coimbra, Apartado 3046, 3001–401, Coimbra, Portugal. e-mail: c.y.henderson@uc.pt

of fine grained sandpaper) or a vertically aligned striated surface. This should only be recorded if it covers more than 50% of the surface.

References

- Chew ML, Giuffrè BM. 2005. Disorders of the distal biceps brachii tendon1. *RadioGraphics* **25**: 1227–1237. DOI:10.1148/rg.255045160.
- Forthman CL, Zimmerman RM, Sullivan MJ, Gabel GT. 2008. Cross-sectional anatomy of the bicipital tuberosity and biceps brachii tendon insertion: relevance to anatomic tendon repair. *Journal of Shoulder and Elbow Surgery* **17**: 522–6. DOI:10.1016/j.jse.2007.11.002
- Henderson CY, Mariotti V, Pany-Kucera D, Villotte S, Wilczak C. 2013. Recording specific enthesal changes of fibrocartilaginous entheses: initial tests using the Coimbra method. *International Journal of Osteoarchaeology* **23**: 152–162. DOI:10.1002/oa.2287
- Henderson CY, Mariotti V, Pany-Kucera D, Villotte S, Wilczak C. 2015. The New “Coimbra method”: a biologically appropriate method for recording specific features of fibrocartilaginous enthesal changes. *International Journal of Osteoarchaeology*. DOI:10.1002/oa.2477
- Mazzocca AD, Cohen M, Berkson E, Nicholson G, Carofino BC, Arciero R, Romeo A a. 2007. The anatomy of the bicipital tuberosity and distal biceps tendon. *Journal of Shoulder and Elbow Surgery* **16**: 122–127. DOI:10.1016/j.jse.2006.04.012
- Nolte M, Wilczak C. 2013. Three-dimensional surface area of the distal biceps enthesis, relationship to body size, sex, age and secular changes in a 20th Century American Sample. *International Journal of Osteoarchaeology* **23**: 163–174. DOI:10.1002/oa.2292