

An unusual coronoid fracture in a fragment of ulna recovered from the Prehistoric site of Buraca da Moira Rock Shelter (Boa Vista, Leiria)

Fratura do processo coronoide da ulna: um caso raro identificado no sítio pré-histórico do Abrigo da Buraca da Moira (Boa Vista, Leiria)



69

Sandra Assis^{1a*}, Rute Branco², Vânia Carvalho^{3,4b}, Rita Dias^{5,6c}, Carlos Duarte^{7d}, Marina Évora^{5,e}, Anne Farias², Trenton Holliday^{8,9}, João Marreiros^{5,6f}, Roxane Matias², Patrícia Monteiro^{2,5,6g}, David Nora^{2h}, Eduardo Paixão^{2,5,6i}, Telmo Pereira^{5,6j}

Abstract In 2015, several disarticulated human skeletal remains were identified in the top layers of the prehistoric site of Buraca da Moira Rock Shelter (Boa Vista, Leiria), during the archaeological excavation carried out under the scope of the EcoPLis — Human Occupations in the Pleistocene Ecotones of the River Lis project. The recovery of chert,

Resumo No ano de 2015, durante a intervenção arqueológica afeta ao projeto EcoPLis: Ocupação Humana Plistocénica nos Ecótonos do Rio Lis foram identificados vestígios osteológicos humanos desarticulados à superfície e nas camadas iniciais do complexo cársico do Abrigo da Buraca da Moira (Boa Vista, Leiria). A recuperação de artefactos em quartzo e sílex,

¹ CRIA — Centro em Rede de Investigação em Antropologia, Universidade Nova de Lisboa, Portugal.

² NAP — Núcleo de Alunos de Arqueologia e Paleoecologia, Universidade do Algarve, Portugal.

³ CIAS — Centro de Investigação em Antropologia e Saúde, Universidade de Coimbra, Portugal.

⁴ Câmara Municipal de Leiria, Portugal.

⁵ ICAREHB — Centro Interdisciplinar de Arqueologia e Evolução do Comportamento Humano, Universidade do Algarve, Portugal.

⁶ Faculdade de Ciências Humanas e Sociais, Universidade do Algarve, Portugal.

⁷ Universidad de Cantabria, Santander, Spain

⁸ Tulane University, New Orleans, United States of America.

⁹ Evolutionary Studies Institute, University of the Witwatersrand, Johannesburg, South Africa.

^a orcid.org/0000-0003-3081-2838, ^b orcid.org/0000-0002-5741-6491, ^c orcid.org/0000-0003-2999-3133,

^d orcid.org/0000-0002-4570-1308, ^e orcid.org/0000-0003-2422-743X, ^f orcid.org/0000-0002-3399-8765,

^g orcid.org/0000-0002-4606-9201, ^h orcid.org/0000-0002-2948-776X, ⁱ orcid.org/0000-0003-0850-1806,

^j orcid.org/0000-0002-7588-2090

* Autor correspondente/Corresponding author: sandraassis78@gmail.com

quartz and quartzite blanks, a schist plate, as well as adornments in bone and shell indicates a Late Neolithic-Chalcolithic chronology. The disarticulated human assemblage, composed of a total of 129 bone and tooth fragments, allowed the estimation of a minimum number of six individuals. Among the remains recovered, an upper portion of an adult right ulna lacking the coronoid process was identified. Replacing it, a semi-oval groove with smooth contours and exposing some trabecular bone was observed. The location, type of bone change, and the observed signs of bone healing are consistent with an uncommon trauma: a fracture of the coronoid process. In the differential diagnosis, both postmortem changes and developmental disturbances were considered but later excluded. The mechanisms that underlie the bone changes are discussed in light of the clinical and paleopathological literature.

Key-words: Trauma; coronoid process of ulna; Late Neolithic-Chalcolithic; disarticulated human remains; Portugal.

Introduction

In 2015, during the first archaeological excavation carried out under the scope of the EcoPLis — Human Occupations in the Pleistocene Ecotones of the River Lis project, disarticulated and frag-

de uma placa de xisto, e de adornos em osso e concha sugerem como cronologia o Neolítico Final/Calcolítico. A análise paleobiológica preliminar dos fragmentos ósseos e peças dentárias recuperados (n=129) permitiu inferir que pertencerão a, pelo menos, seis indivíduos. De entre os elementos analisados macroscopicamente, destacou-se um segmento proximal de uma ulna direita pertencente a um indivíduo adulto. Este fragmento caracterizava-se pela ausência do processo coronóide, e pela presença de uma depressão óssea ovalada com contornos suaves, associada a uma ligeira exposição de osso trabecular. A localização, tipo de alteração e a presença de sinais de remodelação óssea são consistentes com uma lesão traumática incomum: a fratura do processo coronóide. No diagnóstico diferencial foram consideradas, e posteriormente excluídas, alterações de cariz tafonómico e problemas de desenvolvimento. Neste trabalho serão discutidos os mecanismos conducentes à lesão à luz da literatura clínica e paleopatológica.

Palavras-chave: Trauma; processo coronóide da ulna; Neolítico Final/Calcolítico; restos ósseos desarticulados; Portugal.

mentary human skeletal remains were identified in the top layers of a karstic rock shelter located at the site of Buraca da Moira (Boa Vista-Leiria, Portugal) (Figure 1 A-B). The rock shelter, which turned out to be a cave, seems to have different levels of human occupation, and consti-

tutes the remnant of a cave partially destroyed by a former quarry.

The preliminary anthropological analysis of the remains revealed a total of 129 bone and tooth fragments. Due to poor preservation and high fragmentation of the assemblage, only 52.7% (68/129) of the remains allowed a detailed analysis. Despite the small sample size, a minimum number of six individuals, two adults and four non-adults, were estimated based on the recommendations of Herrmann et al. (1990). The non-adult assemblage included individuals between prenatal age (26–30 weeks)

and 11 years old at death. The estimation of the age of death of the immature remains was based on teeth formation and eruption, the stages of epiphyseal union and some bone measurements, as described in Buikstra and Ubelaker (1994), Scheuer and Black (2000), and Schaefer et al. (2009). Adult age-at-death and sex estimations were seriously compromised by the post-mortem destruction of the remains. Even so, the metric analysis of two left tali, using the method of Wasterlain (2000), points to the presence of at least two male individuals. Nevertheless, this diagnosis should be




Figure 1. A. Location of the karstic rock shelter of Buraca da Moira (Leiria, Portugal). B. The Buraca da Moira Rock Shelter.

interpreted with caution, since no other bones from the same individuals, particularly the os coxae and the skull, which are credited as providing the most reliable group of morphological traits for sex estimation, were recovered (for a review, see, e.g., Mays and Cox, 2000; Bruzek and Murail, 2006; Chamberlain, 2006; Garvin, 2012; White et al., 2014). The recovery of a schist plate, adornments in bone, a yet unknown rock and shells such as *Littorina* sp. and *Crassostrea angulate* in association with commingled remains is consistent with a Late Neolithic or Chalcolithic occupation (Pereira et al., 2016). Until now, this type of occupation was unknown from the archaeological record of the region of Leiria.

Among the bone fragments recovered, an upper portion of a right ulna was notable due to its irregular morphology. This paper aims to describe the bone changes observed in the right ulna, discussing the differential diagnosis in light of the clinical and paleopathological literature.

The right ulnar fragment: case description

Circa 9 cm in length, the right ulna preserves the proximal third of the shaft and its proximal end. Albeit incomplete, no major taphonomic changes were noticed on the bone surface. The overall morphology of the ulna and the complete fusion of the proximal epiphysis suggests a mature individual of unknown sex and age-at-death (following

the descriptions depicted in Buikstra and Ubelaker, 1994; Scheuer and Black, 2000; and Schaefer et al., 2009).

The detailed macroscopic observation of the ulnar fragment revealed a striking feature: the absence of the coronoid process. Instead, a semi-oval bone groove (17 mm ML x 12 mm W) with smooth contours was observed. The lesion was located above the ulnar tuberosity and exposed a small patch of trabecular bone. Signs of bone remodeling were noticed bordering the lesion contours (Figure 2 A-D). No joint or enthesal changes, for example, at the site of attachment of brachialis and triceps brachii muscles were observed. No radiographic analysis was performed.

Differential diagnosis

Three possible contributing factors should be considered in the differential diagnosis of the bone changes observed in the right ulnar fragment: (1) taphonomic changes, (2) developmental or congenital anomalies, and (3) trauma. Although post-mortem damage was a common observation in most of the skeletal fragments analyzed, the observed signs of bone healing in the right ulna allowed us to exclude this hypothesis from the differential diagnosis.

Most congenital anomalies arise during morphogenesis at the early stages of embryonic development (Barnes, 2008). According to Barnes (2008: 329), a congenital anomaly is “any prenatal physical

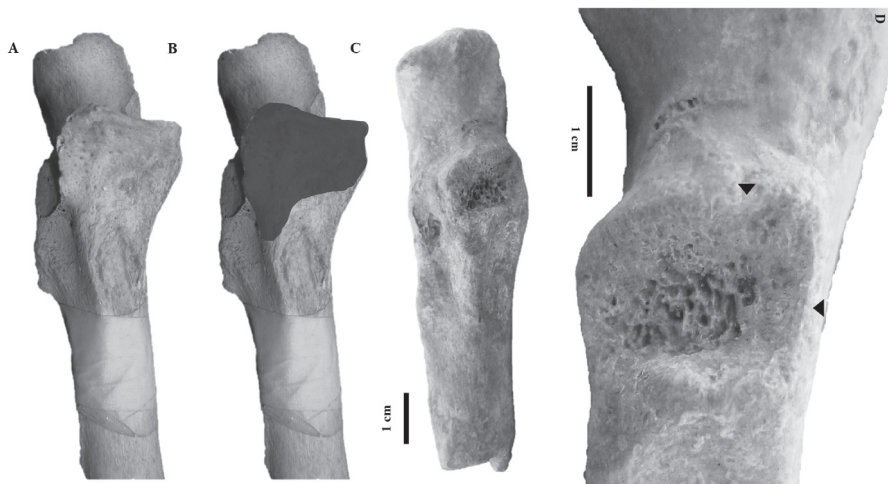

Figure 2. A. Right ulna with an unaffected coronoid process. B. Right ulna showing the affected area, represented by a grey shadow: C. Right ulna recovered at Buraca da Moira Rock Shelter. Note the absence of a large portion of the coronoid process. D. Detail of the affected area exhibiting signs of bone remodeling (black arrowheads).

condition that deviates from what is considered normal". In a developing embryo, several epigenetic, intrinsic and extrinsic factors may impair molecular signaling, interfering with the timing of development and differentiation of the embryonic tissues (Barnes, 2008; 2012). In the human skeleton, some developmental disturbances may cause delay, disorder or absence of tissue segmentation and ossification (Barnes, 2012).

With regard to the upper limb, the morphogenesis of the ulna and radius is vulnerable to disturbances that cause hypoplasia or aplasia (partial or complete absence of a bone), synostosis (presence or persistence of an osseous connection between bones, e.g. radioulnar synostosis), as well as non-union and developmental failure of separate bones (e.g. sty-

loid process of the ulna) (Stevenson, 2006; Barnes, 2008; 2012; Malik and Afzal, 2013). In the present case, the type, shape and location of the lesion are incompatible with any of the developmental anomalies reported for forearm bones. The lesion is more likely to be the result of a traumatic event at the elbow joint that caused a fracture of the coronoid process.

The elbow joint is formed by three dual articulations (humeroradial, humeroulnar, and proximal radioulnar joints) between the humerus, ulna and radius (Whiting and Zernicke, 1998; Sheehan et al., 2013; Bohn et al., 2014; Xiao et al., 2015). The elbow is structurally classified as a synovial trocho-ginglymoid joint with both rotation and hinge functions: it assists the uniplanar flexion/extension of the upper limb and the pronation/su-

pination of the forearm, due to the combined rotations of the proximal and distal radioulnar joints (Whiting and Zernicke, 1998; Wells and Ablove, 2008). The hinge function is provided by the trochlea and capitulum of the humerus, the trochlear notch of the proximal ulna and by the radial head (Wells and Ablove, 2008). The posterior portion of the trochlear notch is formed by the olecranon, and the anterior portion of a triangular-shaped protrusion, the so-called coronoid process (Wells and Ablove, 2008; Xiao et al., 2015). The coronoid process and associated soft tissues — the anterior joint capsule of the elbow, the brachialis muscle and the medial ulnar collateral ligament (MUCL) — are pivotal to stabilize the elbow joint as well as to resist varus stress, prevent backward dislocation and posterior-lateral subluxation (Ring, 2006; Chen et al., 2015).

Fractures of the coronoid process are described as uncommon in the clinical literature. It may occur in association with elbow dislocation — 2% to 15% of patients with elbow dislocation show fractures of the coronoid process — and is credited with causing elbow joint instability (Navalón et al., 2005; Sanchez-Sotelo et al., 2005; Wells and Ablove, 2008). Elbow dislocation — and associated coronoid fracture — may develop after a fall on the elbow or outstretched hand, and is equally observed in sports, daily activities or motor vehicle accidents (for a review see Wells and Ablove, 2008, and authors therein). The mechanisms of injury most commonly associated with

it are axial loading and twisting, elbow resisted flexion, elbow hyperextension, and shear forces created as the coronoid subluxates or dislocates over the trochlea (Trousdale et al., 2001; Wells and Ablove, 2008). In certain circumstances (e.g. low-energy falls from standing height and high energy accidents), posterior dislocation of the elbow may appear combined with fractures of the coronoid process and radial head in a complex injury termed as “terrible triad” (Seijas et al., 2005; Bohn et al., 2014). Isolated coronoid fractures, such as those caused by avulsion of the brachialis muscle, are rare (Gadgil et al., 2002) but have been reported in athletes, such as baseball pitchers (Akagi et al., 2000).

In clinical literature, two different classification systems — generally known as the Regan and Morrey (1989) and the O’Driscoll and colleagues (2003) classification systems — are used to categorize fractures of the coronoid process. Both systems classify fractures into three main types, which are further divided into more specific subtypes based on the severity of the coronoid involvement (Ring, 2006; Sheehan et al., 2013). Whereas the Regan and Morrey system considers the percentage of bone fractured (i.e. type I, avulsion of the coronoid tip; type II, 50% or less of the coronoid process affected; and type III, >50% of the coronoid process affected), as well as the presence or absence of elbow dislocation, the O’Driscoll system regards the anatomic location of the fracture (i.e. type I, includes the tip

of the coronoid process; type II, involves the anteromedial facet of the coronoid process; and type III, includes a fracture at the base [body] of the coronoid process (Regan and Morrey, 1989; O'Driscoll et al., 2003). The last system also values the mechanism of injury and the distribution of the fracture lines, emphasizing the impact on the anteromedial facet and soft tissues (O'Driscoll et al., 2003; Ring, 2006; Sheehan et al., 2013; Wang et al., 2013; Xiao et al., 2015).

Based on the extension of the ulnar lesion, and using both systems previously mentioned, one may broadly classify the case under discussion as a Type III fracture, that is, a large fracture that has disrupted more than 50% of the coronoid process, affecting the body in the process. The non-recovery of the remaining upper limb bones, especially the radius, hampered the establishment of a relationship between the ulna fracture and a case of "terrible triad". Nevertheless, a concurrent dislocation of the elbow cannot be fully excluded from the present diagnosis.

Although the circumstances of injury are difficult to discern from dry bone remains, the absence of the fractured fragments and the presence of signs of bone remodeling seems to suggest that the individual survived to the traumatic event. Moreover, it indicates the occurrence of a fracture complication characterized by nonunion of the fractured bone portions. Nonunion is a recurrent complication of severe coronoid fractures — as it is stiffness — sometimes related to

long periods of immobilization — elbow joint instability, post-traumatic arthrosis, and heterotopic ossification (Trousdale et al., 2001; Ring, 2006). The latter bone changes were not observed in the case in discussion. In fact, the management of large fractures of the coronoid process constitutes a challenge for orthopaedic surgeons, sometimes requiring bone and soft tissues reconstruction (Ring, 2006; Seijas et al., 2005; Manidakis et al., 2012). It is highly possible that the severity of the coronoid fracture and the presence of trauma complications have led to some degree of disability in the right upper limb with a negative impact on the individual's daily activities.

Ulnar fractures in Portuguese prehistoric sites

Trauma lesions are a rare occurrence in skeletal remains from Portuguese prehistoric sites (Silva, 2003). When present, they are most frequently observed in skull remains. For instance, in a review of trauma cases associated with interpersonal violence in Portuguese Neolithic samples, Silva and co-authors (2012) reported a total of 37 skull lesions, most of them characterized by depressed cranial fractures ($n=29$).

In the postcranial skeleton, healed fractures are more frequently reported in the tubular bones of the hand and feet (Silva, 2012), followed by long bones, all predominantly affecting bones of adult individuals (Table 1). With regard to ulna frac-

Table 1. Postcranial bone fractures observed in Portuguese prehistoric sites.

Chronology	Site	Trauma lesions described	References
	Moita do Sebastião (Muge, Salvaterra de Magos)	Healed fracture in the distal third of the right ulna Probable greenstick fracture in the distal third of the right ulna	
Mesolithic	Cabeço da Arruda (Muge, Salvaterra de Magos)	Rib fractures Probable hairline fracture in a left radius Fracture in a left ulna Probable fracture of the olecranon (left ulna) and of the medial distal portion of a left humerus (elbow joint osteoarthritis – secondary trauma complications) Fracture of the right clavicle	Jacks (2004)
	Samoqueira 1 (Sines)	Healed fracture in a humerus Fracture in a metatarsal bone	
Neolithic	Zambujal, (Melides, Grândola)	Probable fracture at the distal end of a left humerus	
Neolithic	Outeiro Alto 2, Hypogaea (Brinches, Serpa)	Healed fracture in a proximal hand phalange	Silva et al. (2015)
Neolithic/ Chalcolithic	Cabeço da Arruda II (Torres Vedras)	Fracture in a proximal foot phalange	Silva (2012)
Neolithic/ Chalcolithic	Monte Canelas I (Alcalar, Portimão)	Healed fractures in four metacarpal bones	Silva and Cunha (2001)
Neolithic/ Chalcolithic	São Paulo II (Almada)	Healed fracture at the distal end of a right ulna Fracture in a 2 nd left metacarpal bone Fracture in a 2 nd right metacarpal bone	
Neolithic/ Chalcolithic	Serra da Roupa (Bombaral)	Healed fracture in the left ischiopubic ramus Fracture in a 3 rd left metatarsal bone Fracture in a 5 th right metatarsal bone Fracture in a proximal foot phalange	Silva (2012)
Neolithic/ Chalcolithic	Poço Velho (Cascais)	Healed fracture in the lower third of a right tibia Healed fracture at the distal end of a right radius and ulna Healed fracture in the midshaft of a right 5 th metacarpal bone Healed fracture in a rib fragment	Antunes-Ferreira (2005)
Neolithic/ Chalcolithic	Paimogo I (Lourinhã)	Healed fracture at the distal end of a left radius Healed fracture in the neck of a right femur (hip fracture) Healed fracture in the neck of a left femur (hip fracture) Healed fracture at the distal end of a left 5 th metatarsal bone	Silva and Ferreira (2008)
Bronze Age	Torre Velha 3 (São Salvador, Serpa)	Healed fracture at the distal end of a right ulna	Fidalgo (2014)
Bronze Age	Torre Velha 3 (São Salvador, Serpa)	Healed fracture in the diaphysis of a right 5 th metatarsal bone Healed fracture in the distal portion of a left clavicle Unconsolidated fracture in the shaft of a left ulna (pseudarthrosis formation)	Coelho (2015)

tures, they have been reported in skeletal assemblages dated from the Mesolithic to the Bronze Age (see Table 1, Mesolithic, n=4: two right, two left; Neolithic/Chalcolithic, n=2: two right; Bronze Age, n=2: one right and one left) and are often described as affecting the lower third of the shaft or the distal end of the ulna.

These findings agree with previously published works. In the paleopathological literature, fractures of the ulna are most frequently observed in the olecranon, shaft (i.e. parry fracture and Monteggia fracture-dislocation) and styloid process, being interpreted as the result of accidents or interpersonal violence (Smith, 1996; Lovell, 1997; Standen and Arriaza, 2000; Judd, 2002; 2004; Djurić et al., 2006; Dommett and Tayles, 2006; Boccione et al., 2011; López et al., 2011; Šlaus et al., 2012; Fernández-Crespo, 2017; Lambert and Welker, 2017). Accordingly, it is possible that the fracture of the coronoid process of the ulna here described constitutes one of the first cases reported in archaeological context, namely in Portuguese territory.

Final remarks

This paper described an unusual lesion observed in a disarticulated and fragmented ulna recovered in the karstic rock shelter of Buraca da Moira, dated to the Late Neolithic or Chalcolithic. The lesion, diagnosed as an extensive fracture of the coronoid process (probably Type III), evolved to a secondary trauma com-

plication characterized by the nonunion of the fractured bone ends. Based on the severity of the fracture, one may assume that the injury had compromised, to some extent, the stability and motion of the individual's right elbow. Moreover, the presence of signs of bone healing seems to suggest a long-term survival, likely associated with some form of social support. A fall on the elbow or an overuse injury related to daily activities are possible explanations for the trauma lesion observed. The non-recovery of the remaining skeleton, namely of the bones from the upper limb, hampered the establishment of more conclusive results with regard to the exact mechanism of injury. Further archaeological excavations at the Buraca da Moira Rock Shelter — given that EcoPLis is an ongoing project — will probably shed light on issues related with the provenance of the remains, their biological characterization and relationship to the funerary space.

Acknowledgments

We would like to thank Fundação para a Ciência e a Tecnologia (project IF/01075/2013), EST, S.A., União de Freguesias de Santa Eufémia e Boa Vista and the City of Leiria for their logistical support. The authors also thank the Editorial Board and the anonymous reviewers whose comments helped to substantially improve the quality of the article. This work received support of Centro em

Rede de Investigação em Antropologia
— UID/ANT/04038/2013.

This work was presented in the *V Jornadas Portuguesas de Paleopatologia*.

78

References

- Akagi, M.; Takayuki, I.; Ikeda, N.; Nakamura, T. 2000. Total avulsion fracture of the coronoïd tubercle caused by baseball pitching. A case report. *The American Journal of Sports Medicine*, 28(4): 580–582. DOI: 10.1177/03635465000280042401.
- Antunes-Ferreira, N. 2005. Paleobiologia de grupos populacionais do Neolítico Final/Calcolítico do Poço Velho (Cascais). Volume 40 de *Trabalhos de Arqueologia*. Lisboa, Instituto Português de Arqueologia.
- Barnes, E. 2008. Congenital anomalies. In: Pinnhasi, R.; Mays, S. (eds.). *Advances in human paleopathology*. Chichester, John Wiley & Sons: 329–362.
- Barnes, E. 2012. *Atlas of developmental field anomalies of the human skeleton*. New Jersey, Wiley-Blackwell. DOI: 10.1002/9781118430699.
- Boccone, S.; Chilleri, F.; Pacciani, E.; Moggi Cecchi, J.; Salvini, M. 2011. The skeleton of a medieval male with multiple traumatic fractures from Piazza della Signoria, Florence, Italy. *International Journal of Osteoarchaeology*, 21(5): 602–612. DOI: 10.1002/oa.1167.
- Bohn, K.; Ipaktchi, K.; Livermore, M.; Cao, J.; Banegas, R. 2014. Current treatment concepts for “Terrible Triad” injuries of the elbow. *Orthopedics*, 37(12): 831–837.

DOI: 10.3928/01477447-20141124-06.

- Bruzek, J.; Murail, P. 2006. Methodology and reliability of sex determination from the skeleton. In: Schmitt, A.; Cunha, E.; Pinheiro, J. (eds.). *Forensic Anthropology and Medicine: complementary sciences from recovery to cause of death*. Tottowa, Humana Press: 225–242. DOI: 10.1007/978-1-59745-099-7_9.
- Buikstra, J. E.; Ubelaker D. 1994. *Standards for data collection from human skeletal remains. Proceedings of a Seminar at the Field Museum of Natural History*. Fayetteville, Arkansas Archaeological Survey, Research Series, 44.
- Chamberlain, A. 2006. *Demography in Archaeology*. Cambridge, Cambridge University Press. DOI: 10.1017/CBO9780511607165.
- Chen, H-w.; Liu, G-d.; Ou, S.; Fei, J.; Zhao, G-s.; Wu, L-j.; Pan, J. 2015. Operative treatment of terrible triad of the elbow via posterolateral and anteromedial approaches. *PLoS ONE*, 10(4): e0124821. DOI: 10.1371/journal.pone.0124821.
- Coelho, M. J. 2015. *Do Calcolítico à Idade do Bronze: Contextos funerários e análise paleobiológica de restos osteológicos humanos exumados das fossas de Torre Velha 3 (São Salvador, Serpa)*. Dissertação de Mestrado em Biologia e Evolução Humana, Departamento de Ciências da Vida, Faculdade de Ciências e Tecnologia, Universidade de Coimbra.
- Djurić, M.; Roberts, C.; Rakočević, Z.; Djonić, D.; Lešić, A. 2006. Fractures in late medieval skeletal populations from Serbia. *American Journal of Physical Anthropol-*

- ogy, 130(2): 167–178. DOI: 10.1002/ajpa.20270.
- Dommett, K. M.; Tayles, N. 2006. Adult fracture patterns in prehistoric Thailand: a biocultural interpretation. *International Journal of Osteoarchaeology*, 16(3): 185–199. DOI: 10.1002/oa.815.
- Fernández-Crespo, T. 2017. New evidence of Early Chalcolithic interpersonal violence in the Middle Ebro Valley (Spain): two arrowhead injuries from the Swallet of Las Yurdinas II. *International Journal of Osteoarchaeology*, 27(1): 76–85. DOI: 10.1002/oa.2445.
- Fidalgo, D. 2014. *Contextos funerários e estudo antropológico dos restos ósseos humanos dos hipogeu de Torre Velha 3 (São Salvador, Serpa): Uma aproximação ao estudo das comunidades humanas do Bronze do Sudoeste*. Dissertação de Mestrado em Biologia e Evolução Humana, Departamento de Ciências da Vida, Faculdade de Ciências e Tecnologia, Universidade de Coimbra.
- Gadgil, A.; Roach, R.; Neal, N.; Maffulli, N. 2002. Isolated avulsion fracture of the coronoid process requiring open reduction in a paediatric patient: a case report. *Acta Orthopædica Belgica*, 68(4): 396–398.
- Garvin, H. M. 2012. Adult sex determination: methods and application. In: Dirkmaat, D. C. (ed.). *A companion to Forensic Anthropology*. Chichester, Blackwell Publishing Ltd.: 239–247. DOI: 10.1002/9781118255377.ch12.
- Herrmann, B.; Grupe, G.; Hummel, S.; Piepenbrink, H.; Schutkowski, H. 1990. *Præhistorische Anthropologie*. Berlin, Springer Verlag. DOI: 10.1007/978-3-642-61514-6.
- Jackes, M. K. 2004. Osteological evidence for Mesolithic and Neolithic violence: problems of interpretation. In: Roksandic, M. (ed.). *Violent interactions in the Mesolithic: evidence and meaning*. BAR International Series 1237. Oxford, Archaeopress: 23–39.
- Judd, M. 2002. Ancient injury recidivism: an example from the Kerma Period of ancient Nubia. *International Journal of Osteoarchaeology*, 12(2): 89–106. DOI: 10.1002/oa.587.
- Judd, M. 2004. Trauma in the city of Kerma: ancient versus modern injury patterns. *International Journal of Osteoarchaeology*, 14(1): 34–51. DOI: 10.1002/oa.711.
- Lambert, P.; Welker, M. 2017. Traumatic injury risk and agricultural transitions: a view from the American Southeast and beyond. *American Journal of Physical Anthropology*, 162(1): 120–142. DOI: 10.1002/ajpa.23103.
- López, B.; Caro, L.; Pardiñas, A. 2011. Type I Monteggia fracture-dislocation in a monk from a 17th–18th century necropolis of Valladolid (Spain). *Anthropological Science*, 119(1): 39–47. DOI: 10.1537/ase.100419.
- Lovell, N. 1997. Trauma analysis in paleopathology. *Yearbook of Physical Anthropology (American Journal of Physical Anthropology)*, 40(25): 139–170.
- Malik, S.; Afzal, M. 2013. Ulnar aplasia, dysplastic radius and preaxial oligodactyly: rare longitudinal limb defect in a sporadic male child. *Journal of Research in Medical Sciences*, 18(9): 818–821.

- Manidakis, N.; Sperelakis, I.; Hackney, R.; Kontakis, G. 2012. Fractures of the ulnar coronoid process. *Injury, International Journal of Care Injured*, 43(7): 989–998. DOI: 10.1016/j.injury.2011.08.030.
- Mays, S.; Cox, M. 2000. Sex determination in skeletal remains. *In: Cox, M.; Mays, S. (eds.). Human osteology: in Archaeology and Forensic Science*. London, Greewich Medical Media Ltd.: 117–130.
- Navalón, L. A.; Ribot, P.; Valle J. A. 2005. Isolated fracture of the coronoid process. *Acta Orthopædica Belgica*, 71: 615–617.
- O'Driscoll, S. W.; Jupiter, J. B.; Cohen, M. S.; Ring, D.; McKee, M. D. 2003. Difficult elbow fractures: pearls and pitfalls. *Instructional Course Lectures*, 52:113–134.
- Pereira, T.; Carvalho, V.; Holliday, T.; Paixão, E.; Monteiro, P.; Évora, M.; Marreiros, J.; Assis, S.; Nora, D.; Matias, R.; Simões, C. 2016. O projeto de investigação arqueológica EcoPLis — Ocupação Humana Plistocénica nos Ecótonos do Rio Lis: enquadramento, objetivos e primeiros resultados. *Cadernos de Estudos Leirienses*, 11: 9–24.
- Regan, W.; Morrey, B. 1989. Fractures of the coronoid process of the ulna. *The Journal of Bone and Joint Surgery*, 71(9): 1348–1354. DOI: 10.2106/00004623-198971090-00011.
- Ring, D. 2006. Fractures of the coronoid process of the ulna. *The Journal of Hand Surgery*, 31(10):1679–1689. DOI: 10.1016/j.jhbs.2006.08.020.
- Sanchez-Sotelo, J.; O'Driscoll, S.; Morrey, B. 2005. Medial oblique compression fracture of the coronoid process of the ulna. *Journal of Shoulder and Elbow Surgery*, 14(1): 60–64. DOI: 10.1016/j.jse.2004.04.012.
- Schaefer, M.; Black, S.; Scheuer, L. 2009. *Juvenile osteology: a laboratory and field manual*. Amsterdam, Elsevier.
- Scheuer, L.; Black, S. 2000. *Developmental juvenile osteology*. San Diego, Academic Press.
- Seijas, R.; Joshi, N.; Hernández, A.; Catalán, J.M.; Flores, X. 2005. Terrible triad of the elbow—role of the coronoid process: a case report. *Journal of Orthopaedic Surgery*, 13(3): 296–299. DOI: 10.1177/230949900501300314.
- Sheehan, S.; Dyer, G.; Sodickson, A.; Patel, K.; Khurana, B. 2013. Traumatic elbow injuries: what the orthopedic surgeon wants to know. *RadioGraphics*, 33(3): 869–888. DOI: 10.1148/rg.333125176.
- Silva, A. M. 2003. Portuguese populations of late Neolithic and Chalcolithic periods exhumed from collective burials: an overview. *Anthropologie*, 41(1–2): 55–64.
- Silva, A. M. 2012. *Antropologia funerária e Paleobiologia das populações portuguesas (litorais) do Neolítico Final/Calcolítico*. Lisboa, Fundação Calouste Gulbenkian, Fundação para a Ciência e Tecnologia.
- Silva, A. M.; Boaventura, R.; Ferreira, M. T.; Marques, R. 2012. Skeletal evidence of interpersonal violence from Portuguese Late Neolithic collective burials: an overview. *In: Schulting, R.J.; Fibiger, L. (eds.). Sticks, stones, and broken bones: Neolithic violence in a European perspective*. Oxford, Oxford University Press: 317–340. DOI: 10.1093/acprof:oso/bl/9780199573066.003.0017.

- Silva, A. M.; Cunha, E. 2001. Paleopathological study of the community exhumed from the Hipogeu of Monte Canelas I (Alcalar, Portugal). *In: Sánchez Sánchez, J. (ed.). Actas do V Congresso Nacional de Paleopatologia*, Alcalá la Real (Espanha): 353–356.
- Silva, A. M.; Fernandes, A. I.; Valera, A.; Filipe, V. 2015. Funerary practices and anthropological data from the Neolithic hipogea from Outeiro alto 2 (preliminary results). *In: Rocha, L.; Bueno-Ramirez, P.; Branco, G. (eds.). Death as Archaeology of Transition: thoughts and materials*. Papers from the II International Conference of Transition Archaeology: Death Archaeology, BAR International Series 2708, 29th April–1st May 2013. Oxford, Archaeopress: 239–243.
- Silva, A. M.; Ferreira, M. T. 2008. Sinais de trauma na população do Neolítico Final/Calcolítico do Tholos de Paimogo I. *In: Hernández Pérez; Soler Díaz, M.; López Padilla, J. (eds.). Actas del IV Congreso del Neolítico Peninsular*, Alicante (Espanha), 27–30 Noviembre 2006. Alicante, MARQ — Museo Arqueológico de Alicante: 129–130.
- Šlaus, M.; Novak, M.; Bedić, Z.; Strinović, D. 2012. Bone fractures as indicators of intentional violence in the eastern Adriatic from the antique to the late medieval period (2nd–16th century AD). *American Journal of Physical Anthropology*, 149(1): 26–38. DOI: doi.org/10.1002/ajpa.22083.
- Smith, M. 1996. 'Parry' fractures and female-directed interpersonal violence: Implications from the Late Archaic Period of West Tennessee. *International Journal of Osteoarchaeology*, 6(1): 84–91. DOI: 10.1002/(SICI)1099-1212(199601)6:1<84::AID-OA262>3.0.CO;2-G.
- Standen, V.; Arriaza, B. 2000. Trauma in the pre-ceramic coastal populations of northern Chile: violence or occupational hazards? *American Journal of Physical Anthropology*, 112(2): 239–249. DOI: 10.1002/(SICI)1096-8644(2000)112:2<239::AID-AJPA9>3.0.CO;2-3.
- Stevenson, R. 2006. Limbs. *In: Stevenson, R.; Hall J. (eds.). Human malformations and related anomalies*. Oxford, Oxford University Press: 835–934.
- Trousdale, R.; Steinmann, S.; McKay, P. 2001. Fractures of the olecranon and coronoid process. *Orthopaedic Surgery*, 7(3): 3–12.
- Wang, X.; Chang, S.-M.; Yu, G.-r. 2013. Antero-medial coronoid facet fractures. *European Journal of Orthopaedic Surgery & Traumatology*, 23(3): 251–255. DOI: 10.1007/s00590-012-0990-3.
- Wasterlain, R. S. 2000. *Morphé: análise das proporções entre os membros, dimorfismo sexual e estatura de uma amostra da coleção de esqueletos identificados do Museu de Antropologia da Universidade de Coimbra*. Dissertação de mestrado em Evolução Humana, Departamento de Antropologia, Faculdade de Ciências e Tecnologia, Universidade de Coimbra.
- Wells, J.; Ablove, R. 2008. Coronoid fractures of the elbow. *Clinical Medicine & Research*, 6(1): 40–44. DOI: 10.3121/cmr.2008.753.
- White, T. D.; Black, M. T.; Folkens, P. A. 2014. Hu-

man Osteology. 3rd Edition. Burlington, Elsevier Academic Press.

Whiting, W.; Zernicke, R. 1998. *Biomechanics of musculoskeletal injury*. Champaign, Human Kinetics.

Xiao, K.; Zhang, J.; Li, T.; Dong, Y-l.; Weng, X-s. 2015. Anatomy, definition, and treatment of the “terrible triad of the elbow” and contemplation of the rationality of this designation. *Orthopaedic Surgery*, 7(1):13–18. DOI: 10.1111/os.12149.